Fluorescence Angiography in Limb Salvage

Ryan H. Fitzgerald, DPM, FACFAS
Associate Professor of Surgery-University Of South Carolina School of Medicine, Greenville

Etiology of Lower extremity wounds

GREENVILLE HEALTH SYSTEM

Neuropathy
- Sensory
- Motor
- Autonomic

Minor Trauma / Infection

Vascular Insufficiency
- Distal vessels
- Poor collateral
- Medial calcinosis

Pressure
- Increased Loading forces
- Defective reparative systems

WIFI

- Adequate tissue perfusion is vital to the success of any limb salvage attempt in the clinic or in surgery

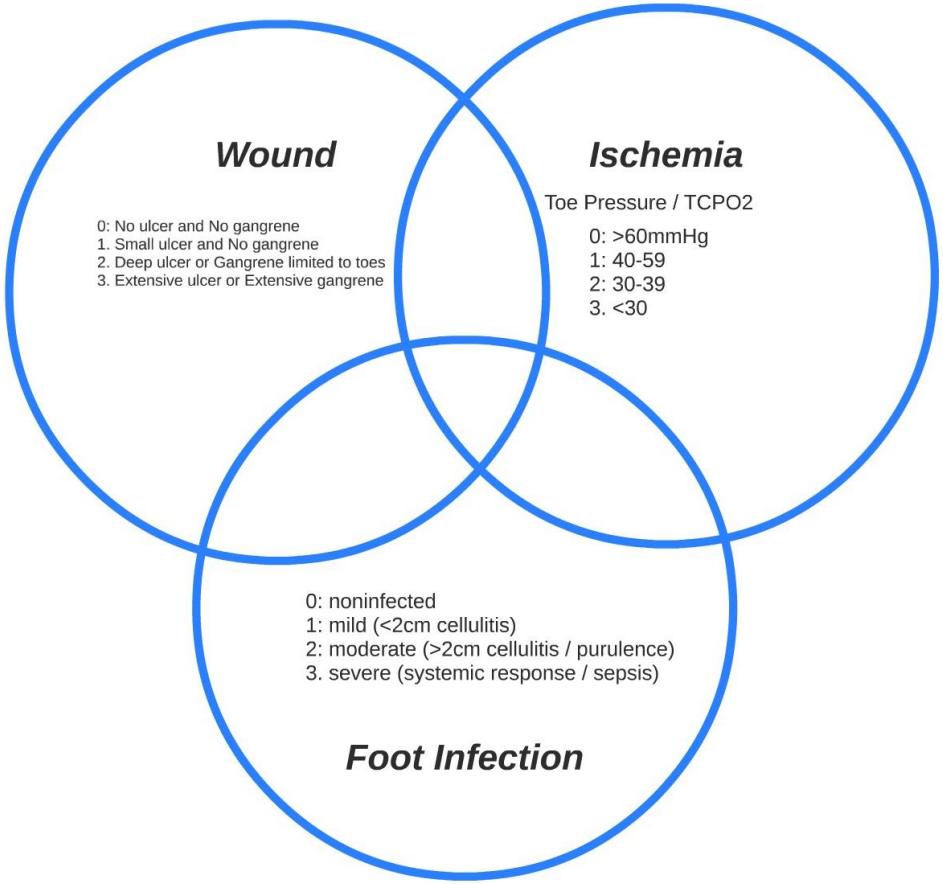

The **Society for Vascular Surgery Lower Extremity** Threatened **Limb Classification System**: risk stratification based on wound, ischemia, and foot infection (WIfI). 1. J Vasc Surg.Oct 12, 2013

Tissue perfusion

GREENVILLE HEALTH SYSTEM

- Tissue perfusion is a key indicator of tissue health, crucial to surgical success and the body's ability to heal
  - Supply vs. Demand
- Even a few hours of impaired perfusion can cause irreversible damage and costly complications
- Despite excellent surgical techniques, perfusion-related complications still occur, especially in complicated, soft tissue reconstructive procedures

Perfusion-Related Complications

Image courtesy of Dr. Geoffrey Gurtner, Stanford, CA

57 y.o. patient with bilateral DIEP flaps:

- Both free flaps were completely healthy
- Mastectomy flap borders were widely necrotic at 2-week follow-up
- Patient required 3 additional surgeries

GREENVILLE HEALTH SYSTEM

Perfusion Assessment in Limb Salvage

Conventional Vascular Assessment Modalities

GREENVILLE HEALTH SYSTEM

- Essential Pre op Exam
  - Non-invasive
    - ABI, TBI
    - Doppler, PVR
    - PPG, T_cpO^2
    - Laser Doppler
    - SPP
  - Invasive (Angiogram)
- Large vessel disease?
- Functional microvascular disease?
  - Palpable pulses with distal disease

Challenges to Conventional Assessment

GREENVILLE HEALTH SYSTEM

<u>TcpO2</u>

- 60-90 Minutes
- Does not provide a visual assessment

ABI

- Large vessel assessment
- Not appropriate in all patients

Doppler

- User dependent
- Large vessel assessment

Pedal Pulses

- Subjective

Skin Perfusion Pressure

- Uses the principles of Laser Doppler
- Static assessment

Hopf et al., Guidelines for the treatment of arterial insufficiency ulcers. *Wound Repair and Regeneration*. 2006 *14*, 693-710
Robson et al., Guidelines for the treatment of venous ulcers. *Wound Repair and Regeneration*. 2006, *14*, 649-662
Steed et al., Guidelines for the treatment of diabetic ulcers. *Wound Repair and Regeneration*. 2006, *14*, 680-692

What is Ischemia?

GREENVILLE HEALTH SYSTEM

Ischemia = Demand > Supply

- Absolute Ischemia
  - lack of flow in normal, resting limb
- Relative Ischemia
  - lack of flow under stress
  - supply is inadequate for the metabolic demands of the tissue bed in <u>current</u> clinical situation
- FA allows interoperative visualization of tissue perfusion to allow for critical evaluation of both!

Perfusion Pathophysiology

GREENVILLE HEALTH SYSTEM

Ischemia in the presence of tissue injury initiates a downward spiral ending in limb loss

GREENVILLE HEALTH SYSTEM

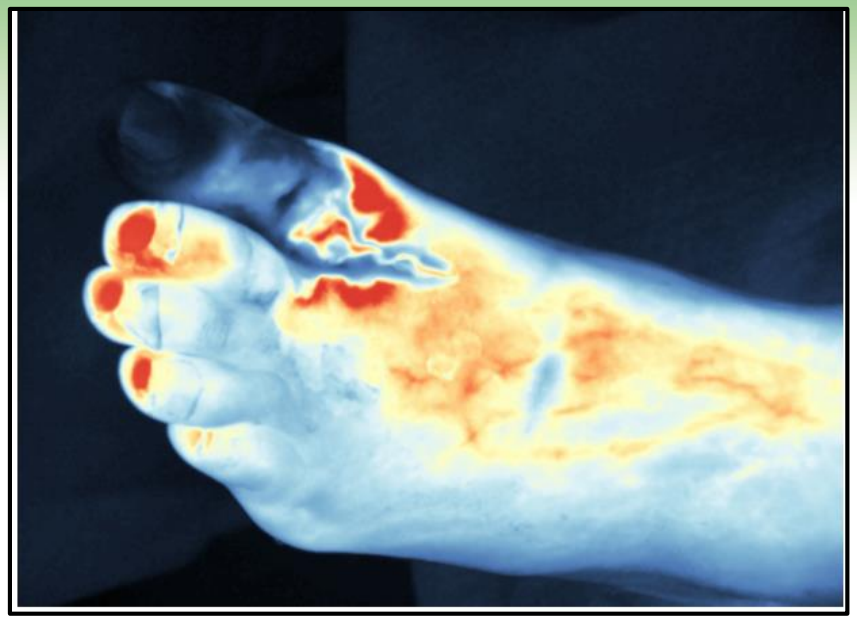

Fluorescence Angiography (FA)

What is Fluorescence Angiography?

- Fluorescence angiography is a diagnostic technique that uses IV fluorescent dye Indocyanine Green (ICG) injected IV to allow the sequential visualization of skin perfusion

What is Fluorescence Angiography?

Fluorescence imaging system that provides clinicians with a real-time visual assessment of tissue perfusion in patients with non-healing wounds

FA: Real time perfusion Information

GREENVILLE HEALTH SYSTEM

FA initially utilized in Retinal Imaging

Fluorescence Angiography (FA)

GREENVILLE HEALTH SYSTEM

- Indications:
  - Used in capturing and viewing fluorescence images for the visual assessment of blood flow, as an adjunctive method for the surgeon's evaluation of tissue perfusion, and related tissue-transfer circulation in tissue, and free flaps used **in plastic, micro-and reconstructive surgical procedures**
  - Intended to provide fluorescence for the visual assessment of blood flow in vessels and related tissue perfusion during **gastrointestinal surgical procedures**
  - Intended to provide fluorescence images for the visual assessment of blood flow in vessels and related tissue perfusion during **cardiovascular surgical procedures***
  - Intended to intraoperatively enable surgeons to visually assess blood flow and related tissue perfusion during **organ transplant procedure**

Enables real-time visualization of tissue perfusion from head-to-toe

GREENVILLE HEALTH SYSTEM

Assessing forehead flap perfusion post inset

Photo courtesy of Dr. Christopher Dress, FL.

Visualizing perfusion of mastectomy flap

Photo courtesy of Dr. Albert Losken, GA.

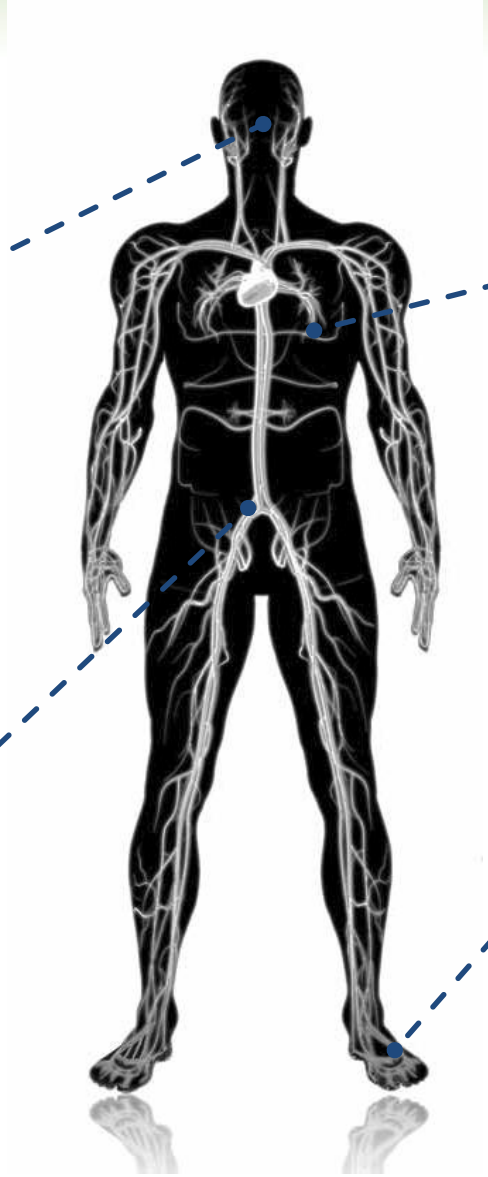

Visualizing perfusion of the small bowel during ostomy creation

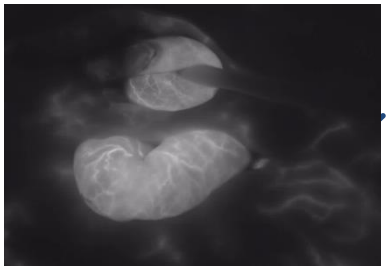

Photo courtesy of Dr. Robert Beart, CA

Visualizing perfusion prior to amputation to optimize clinical plan

Photo courtesy of Dr. Larry Suecof, FL

History of perfusion assessment with Indocyanine Green (ICG)

First used in the 1970's during retinal angiography

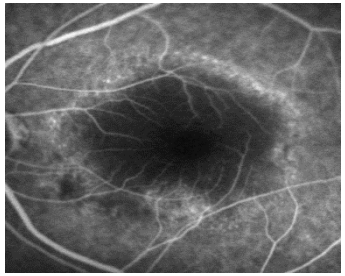

SPY used to assess skin perfusion in plastic surgery in 2007

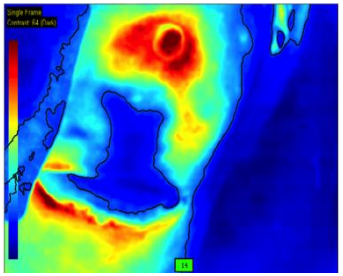

SPY fluorescence technology developed in 1999

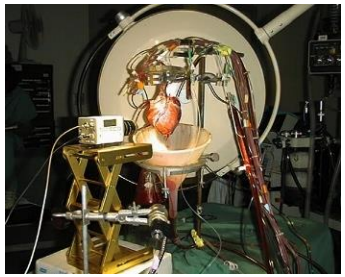

SPY FDA cleared for organ transplant and GI procedures

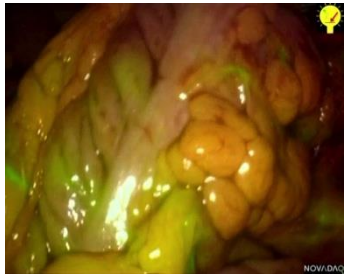

SPY introduced to US market for cardiac surgery applications in 2005

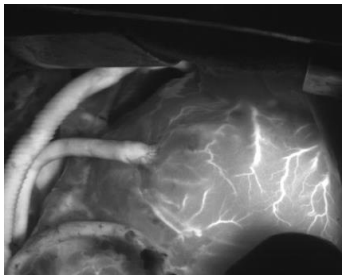

LUNA developed and introduced into wound care procedures in 2013

The FA Setup

GREENVILLE HEALTH SYSTEM

Multi-directional imaging arm

26” dual LCD monitors

SPY Fluorescence imaging head

High-definition color printer

How does FA work??

GREENVILLE HEALTH SYSTEM

- It provides three major types of information:
  - Allows surgeons to visualize microvascular blood flow and perfusion in tissue intraoperatively
  - The flow characteristics in the blood vessels as the dye reaches the tissues
  - Allows for qualitative and quantitative analysis of the patency of circulation to allow for dynamic surgical planning
    - Allowing for focused intraoperative decisions thus leading to reduced rates of postoperative complications and decrease healthcare costs

Indocyanine Green

- Developed by Kodak in the 1950's
- Widely used in medical applications since the 1970's:
  - Retinal angiography
  - Liver function and cardiac output tests
- Strong record of safe clinical use
- Excreted hepatically – not contraindicated in patients with compromised renal function. Non-nephrotoxic
- 3-5 minute half-life
- Only contraindication – should be used with caution in patients that have a history of sensitivity to iodides

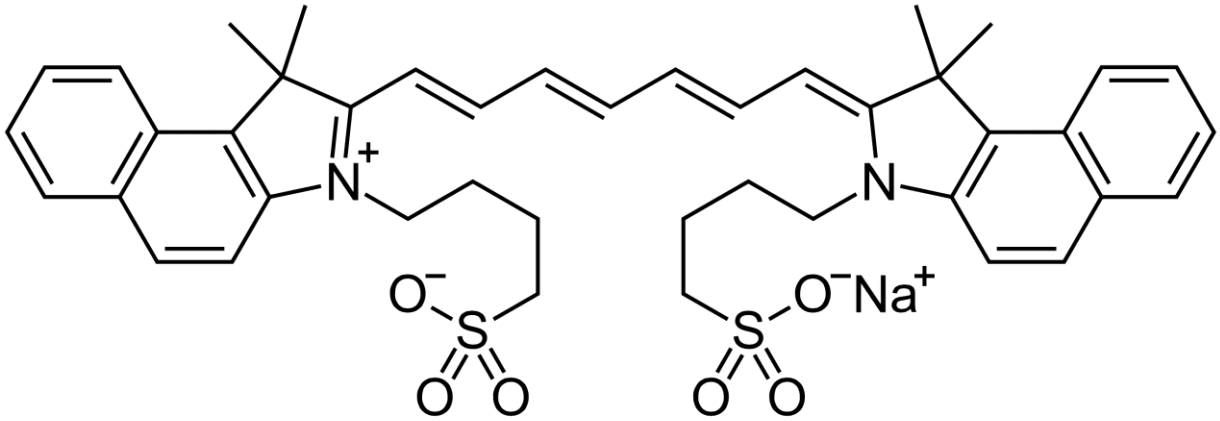

How FA Works

GREENVILLE HEALTH SYSTEM

1. Indocyanine Green injected intravenously

2. Low-level light source excites ICG, fluorescence captured in real-time and displayed on monitor

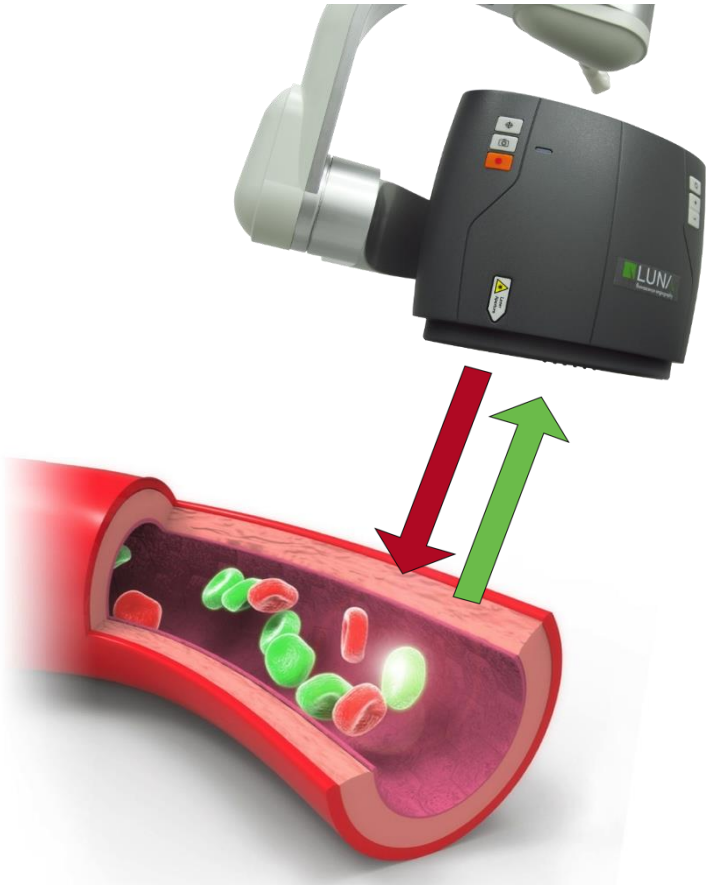

Clinical Benefits

- Qualitative and Quantitative Assessment of tissue perfusion in non-healing wounds

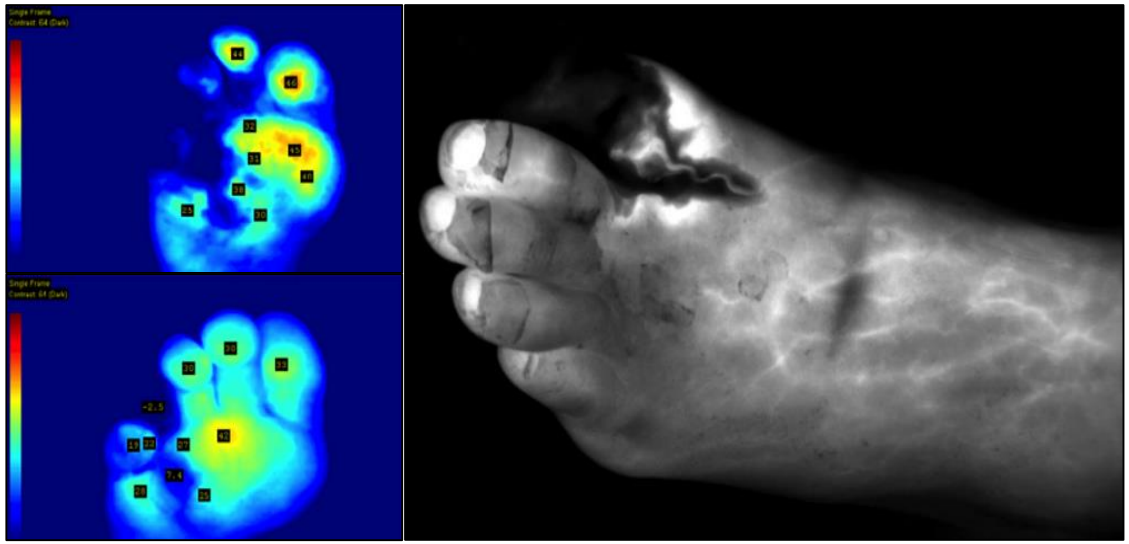

Benefits of FA

GREENVILLE HEALTH SYSTEM

- Enhances intraoperative visualization of blood flow and tissue perfusion in real-time
- Quick clearance of the ICG fluorescence agent allows for multiple images throughout a procedure
- Improves understanding of individual patient vascular flow and tissue perfusion, which may help the surgeon optimize the clinical plan and achieve better clinical outcomes

Correlation to clinical outcomes[1]

GREENVILLE HEALTH SYSTEM

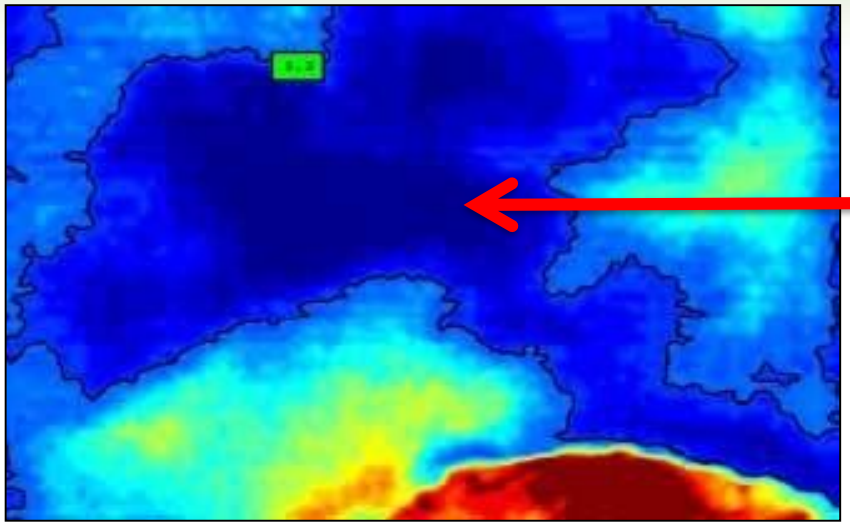

Images courtesy of Dr. John Murray, Illinois

Intraoperative FA image: assisted surgeon in identifying a large area of poor perfusion on the right mastectomy flap during immediate reconstruction.

Postoperative image: illustrates mastectomy flap necrosis correlating with the SPY Elite® System image to the left.

Colorization aids in assessment of perfusion.

1. Newman, M. et al. Intraoperative laser-assisted indocyanine green angiography for the evaluation of mastectomy flaps in immediate breast reconstruction. *Jrnl of Reconstructive Microsurg*. 2010; 26[7]: 487-492.

Correlates to clinical outcomes[1]

GREENVILLE HEALTH SYSTEM

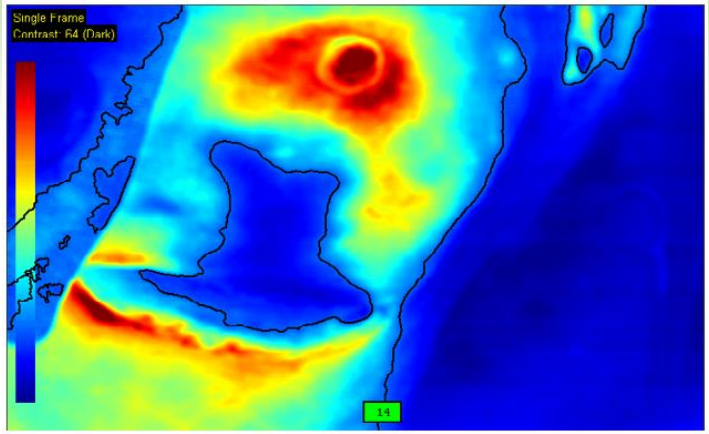

Intraop SPY® System image

Images courtesy of Dr C. Andrew Salzberg, NY

3 days post-op

7 days post-op

1. Newman, M. et al. Intraoperative laser-assisted indocyanine green angiography for the evaluation of mastectomy flaps in immediate breast reconstruction. *Jrnl of Reconstructive Microsurg.* 2010; 26(7): 487-492.

Benefits of FA

GREENVILLE HEALTH SYSTEM

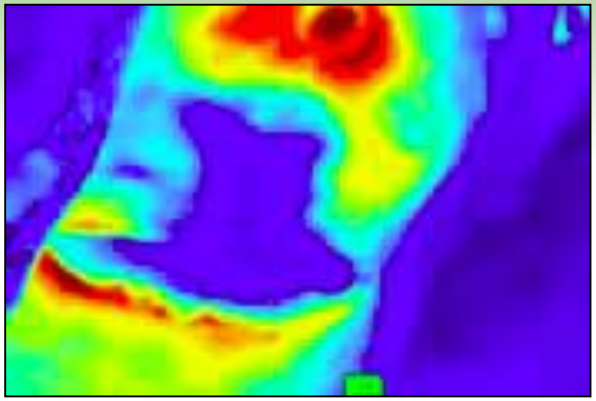

Contour mapping provides the surgeon with actionable information that can be used before and during the procedure

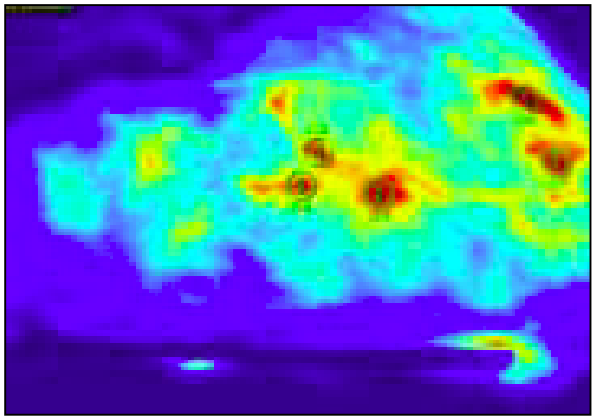

Allows surgeon to analyze and identify perforator perfusion zones before committing to flap design



Objectively applies values to analyze images and further assess tissue perfusion

Utilization of Fluorescence Angiography (FA) Imaging Systems

Installed Base by Product

GREENVILLE HEALTH SYSTEM

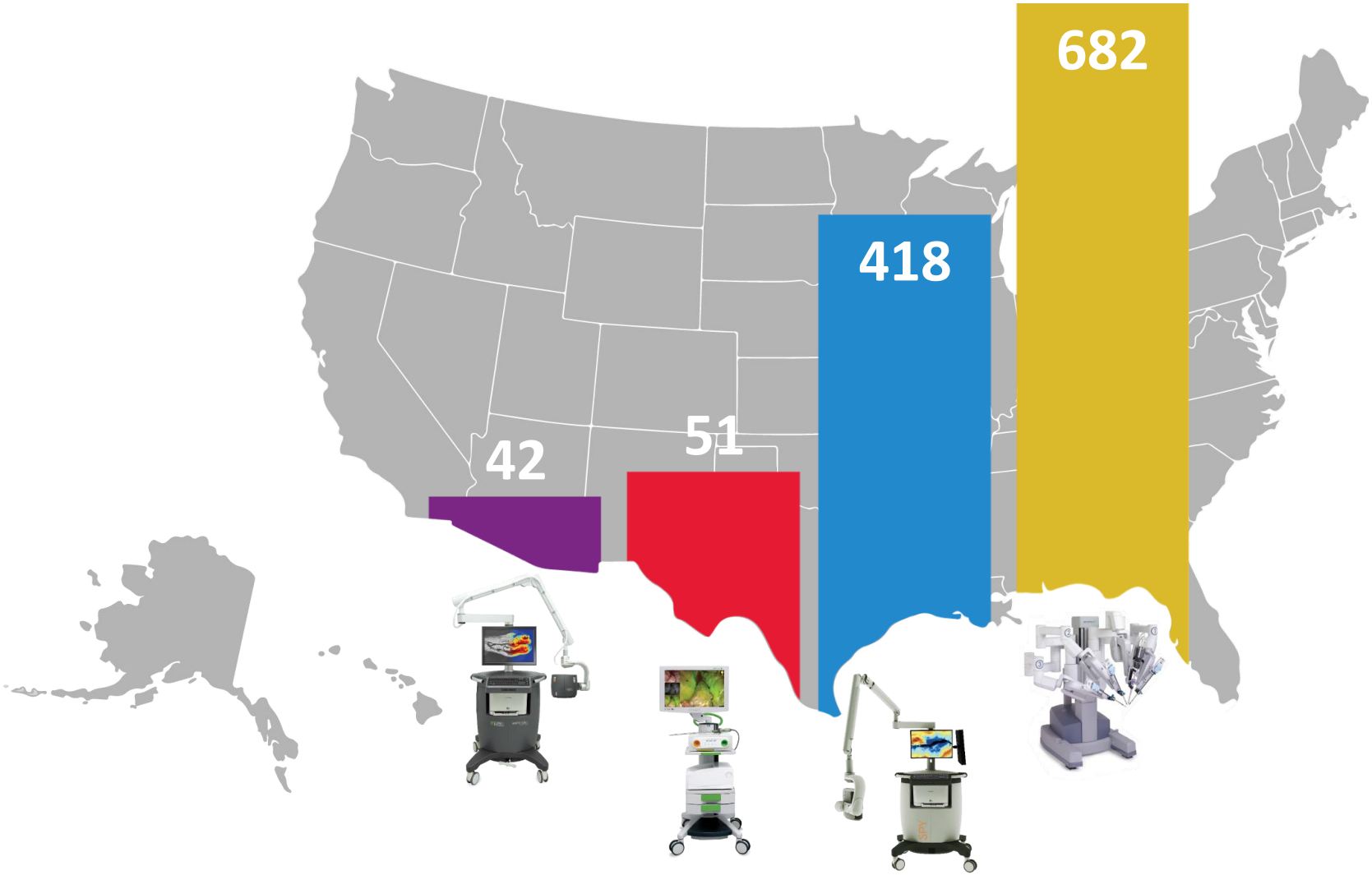

What does the literature say?

GREENVILLE HEALTH SYSTEM

More than 85 peer-reviewed journal articles have demonstrated that the use of FA positively impacts outcomes and reduces healthcare costs

Why? Decreased rate of revision…

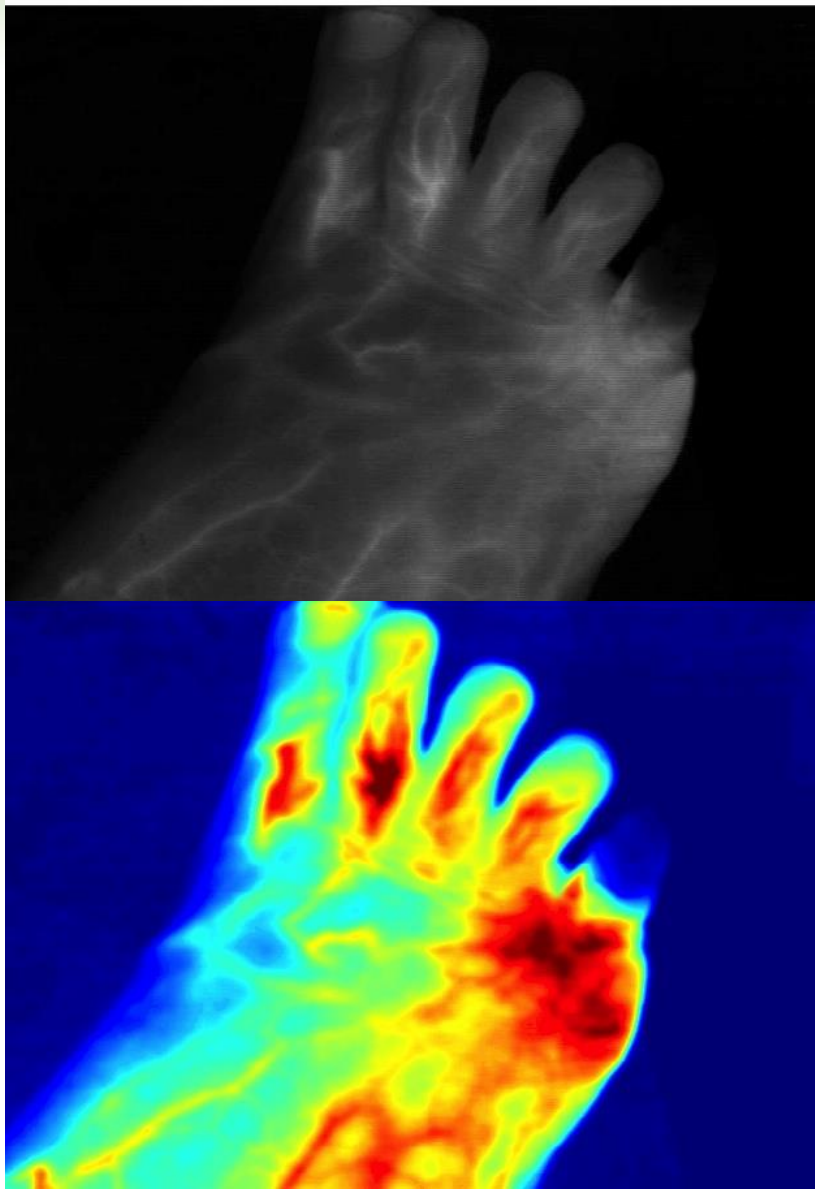

Limb Salvage Applications of FA

GREENVILLE HEALTH SYSTEM

- Fluorescence Angiography provides clinicians with real-time visualization of tissue perfusion in patients with diabetic foot ulcers and non-healing wounds.

- Its specific advantages include:
  - Providing a more reliable assessment of tissue perfusion than any other available technology
  - Quantifying the impact of various wound-healing techniques over time on the quality of tissue perfusion
  - Assisting physicians in defining the optimal care pathway to maximize limb salvage

Clinical Applications of Fluorescent Angiography in Limb Preservation

Clinic

- – Assess baseline skin perfusion
- – Assess perfusion pre and post vascular intervention
- – Predicts capacity for wound healing
- – Predict level of healing (Amputations)
- – Aid to Debridement and assessment of advanced wound care modalities

OR

- – Access viability of flaps – pre and post closure

Comparative Ingress and Egress Studies Post Intervention

GREENVILLE HEALTH SYSTEM

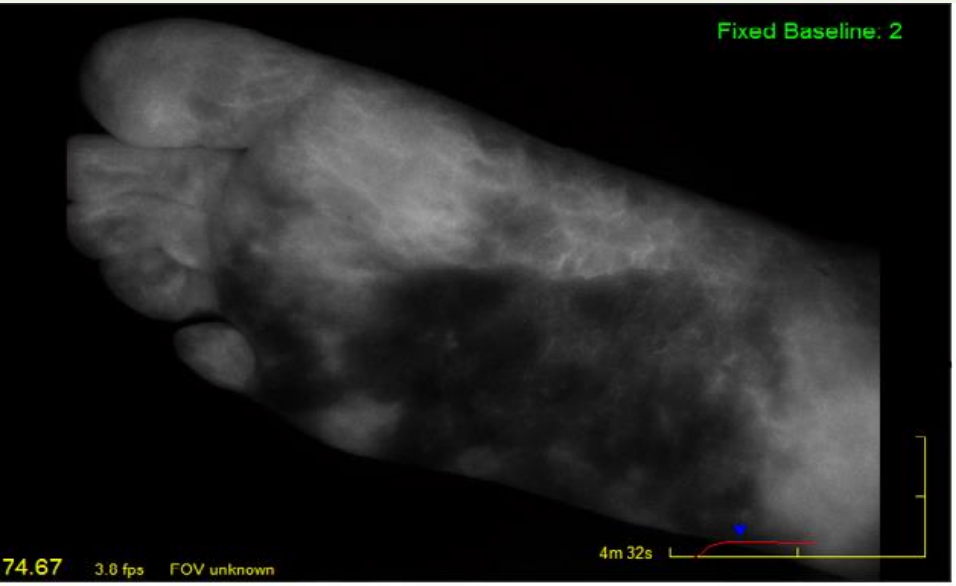

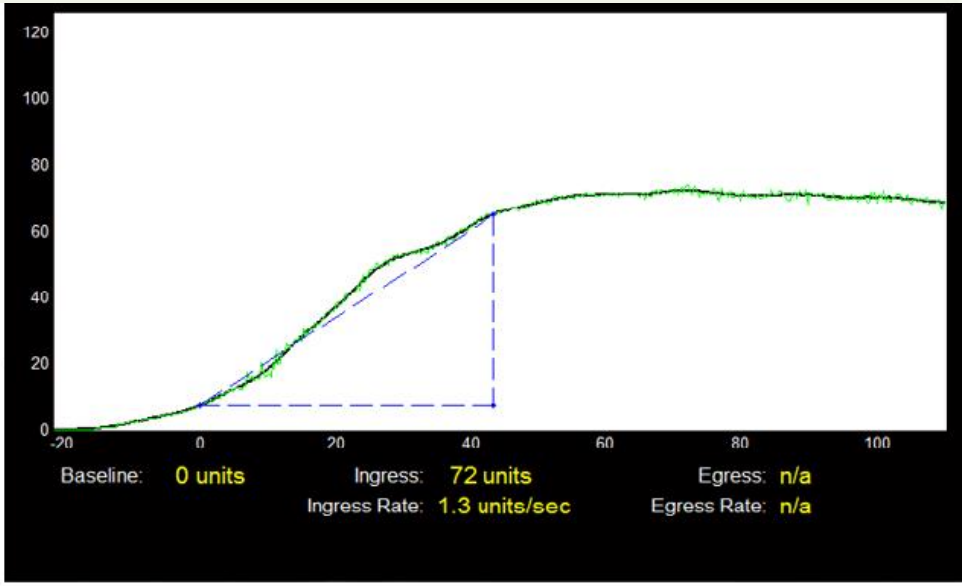

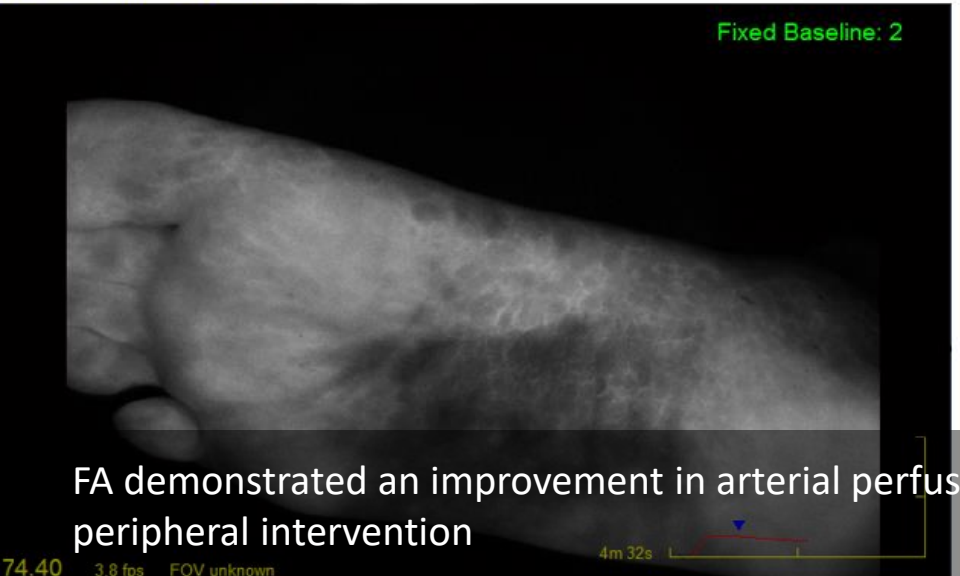

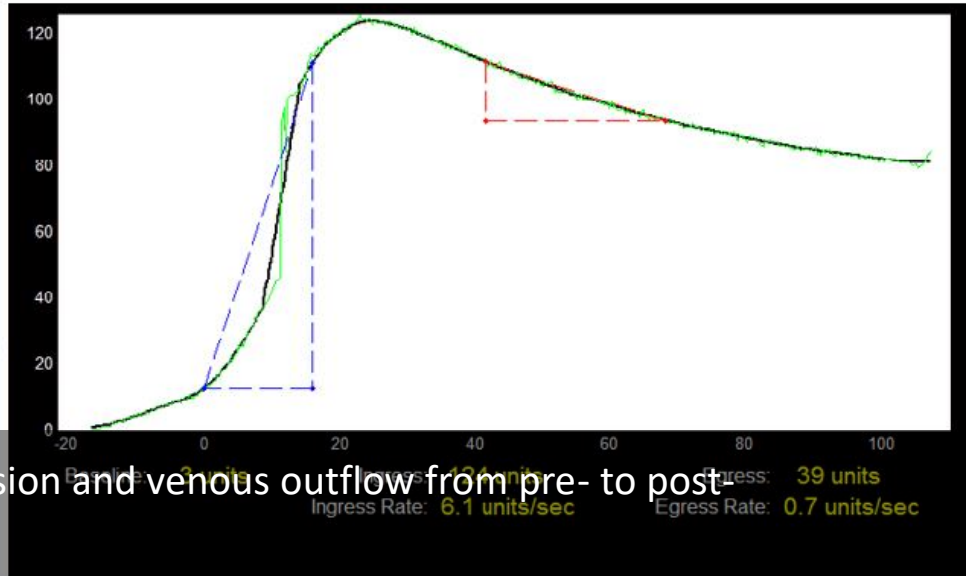

FA demonstrated an improvement in arterial perfusion and venous outflow from pre- to post-peripheral intervention

Quantitative Analysis

GREENVILLE HEALTH SYSTEM

FA demonstrated a marked improvement in perfusion to the 3rd and 5th digits on the right foot post intervention

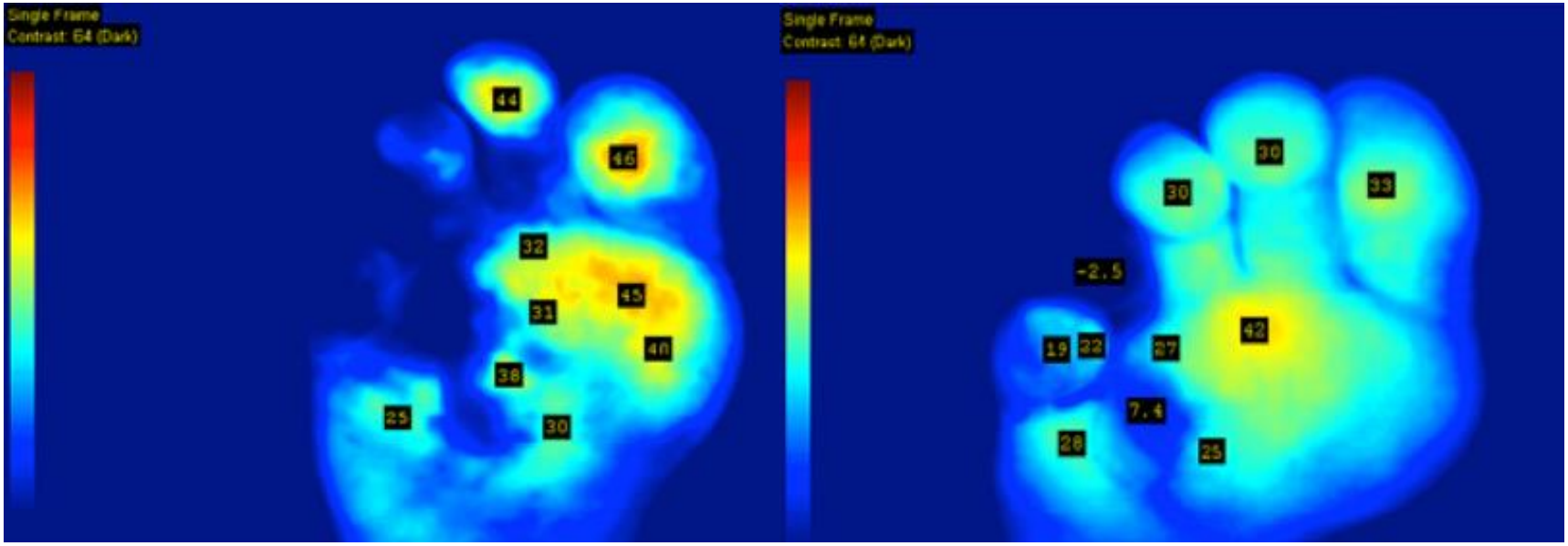

Pre-vascular intervention

Post-vascular intervention

Perry et al., Intraoperative Fluorescence Vascular Angiography: During Tibial Bypass, Journal of Diabetes Science and Technology, 2012

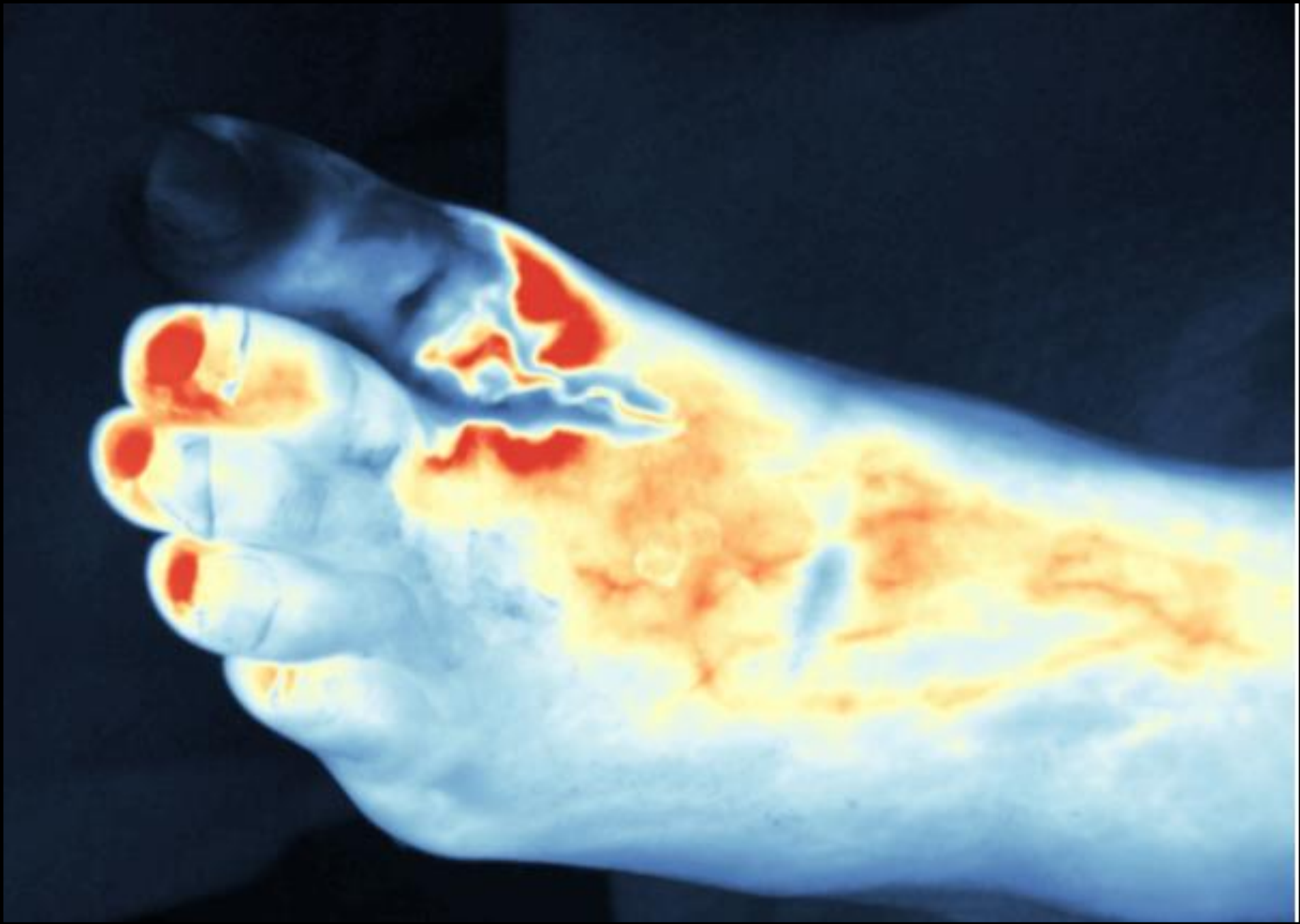

- TCOM readings were inconclusive
- A clear plan for treatment was difficult to determine
- Based on visual inspection, the middle three toes of the left foot looked relatively well perfused
- **FA imaging indicated otherwise.**

- In this patient, TCOM measurements were low.
- FA provided information that was otherwise unavailable
- **FA images demonstrated adequate perfusion to the wound bed in the area that was in question.**

Conclusions

GREENVILLE HEALTH SYSTEM

- Even with years of clinical experience and advancements in technique, complications can still occur following surgery
- Many complications may occur due to the poor quality of blood supply to the affected organ/tissue
- FA allows surgeons to visualize and assess perfusion intraoperatively in real time, allowing for improved outcomes with decreased morbidity and mortality rates.
- The Future?

Questions?

GREENVILLE HEALTH SYSTEM