# *Medial Displacement Calcaneal Osteotomy*

*Michelle Butterworth, DPM, FACFAS*
*Kingstree, SC*

# *Disclosures*

- *MTF: Consultant*
- *Talar Capital Partners: Director, Financial Investment*

# ADULT ACQUIRED FLATFOOT

*Adult Acquired Flatfoot*

*Fixed HF valgus*
*Degenerative changes*

*Arthrodesis*

*Reducible HF valgus*
*Absence of DJD*

*Reconstruction*

# SPECTRUM OF DEFORMITY

- *Stage 1*
  - *Chronic Tenosynovitis*
  - *No Deformity*
- *Stage 2*
  - *Muscle-Tendon Imbalance*
  - *Reducible Flatfoot Deformity*
- *Stage 3*
  - *Hindfoot Arthritis*
  - *Fixed Flatfoot deformity*
- *Stage 4*
  - *Ankle Valgus*
  - *Deltoid Insufficiency*

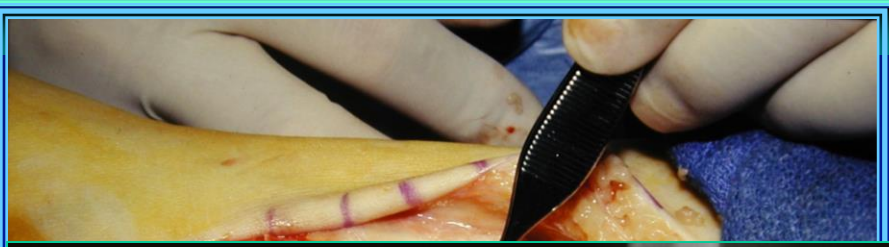

# *Stage II PTTD*

- ***Muscle-Tendon Imbalance leads to foot and ankle dysfunction and subsequent deformity***
- **Deformity is supple and passively correctable**
  - *PTT*
    - *Attenuated*
    - *Functionally incompetent*
    - *Degenerative PT tendinosis*
  - *Achilles tendon contracture*
  - *Peroneal tendons*
    - *Contracture*
    - *Functional advantage*

# *ADULT ACQUIRED FLATFOOT*

## This Is A Triplanar Deformity!

# *ADULT ACQUIRED FLATFOOT*
## *Surgical Goals*

- *Restore the Tripod*
- *Maintain Hindfoot ROM*
- *Correct the Tendon/Muscle Imbalance*

# *Is there a correct answer?*

*104 foot and ankle orthopedists surveyed*

- *88% would use preserve the STJ and TNJ*
- *73% medializing calcaneal osteotomy*
- *41% lateral column lengthening*
- *15% medial column procedure*
- *12% would perform an arthrodesis*
- *94% would augment the PTT*
- *54% repair the spring ligament*
- *70% address the equinus with posterior lengthening*
- ***Conclusions: there is a wide variety of approaches to the stage 2 flatfoot***

(Hiller, Pinney. Foot Ankle, 2003)

# CLINICAL EVALUATION

*STJ in neutral*

↓

*Attempt to lock MTJ*

↓ *Acceptable* — *Posterior*

↓ *Unacceptable* — *Anterior*

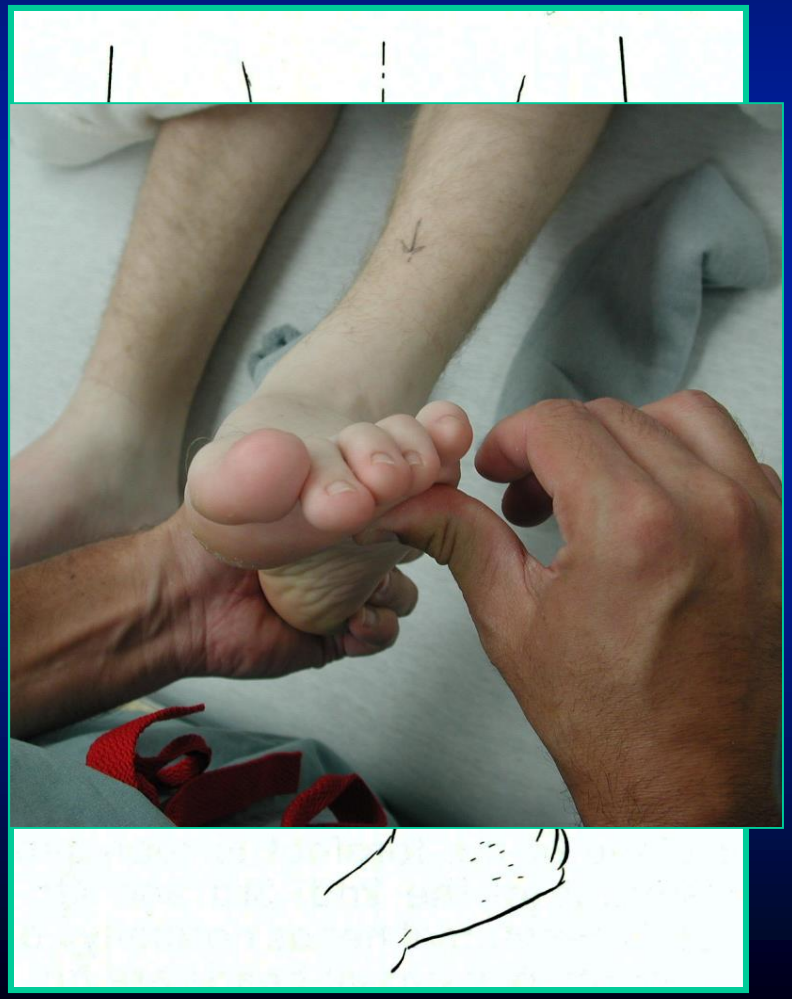

# CALCANEAL OSTEOTOMIES

*Reconstructive Options*

*Moderate valgus HF*
*Stable MTJ*
*Medial symptoms*
*TFMA-low*

*MDCO*

*Severe valgus HF*
*Absence of MTJ locking*
*Lateral symptoms*
*TFMA-high*

*Evans,CCJ fusion,*
*Double osteotomy*

# *Posterior Calcaneal Osteotomy*

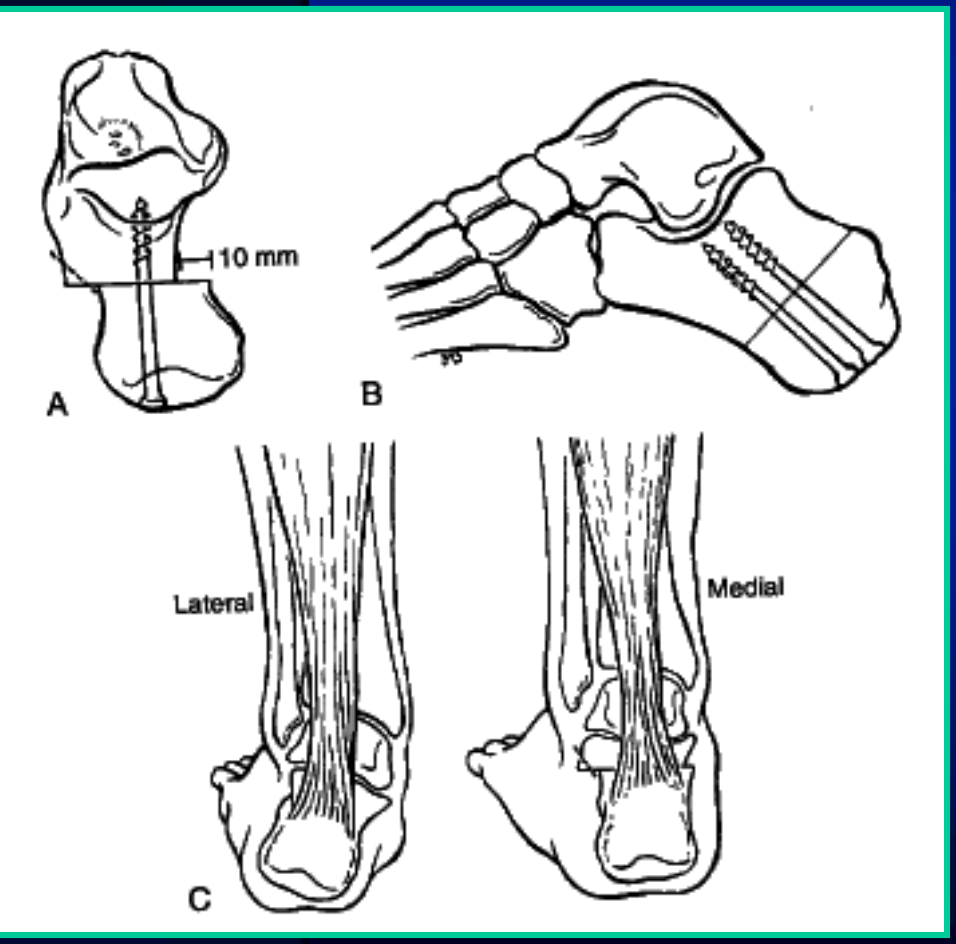


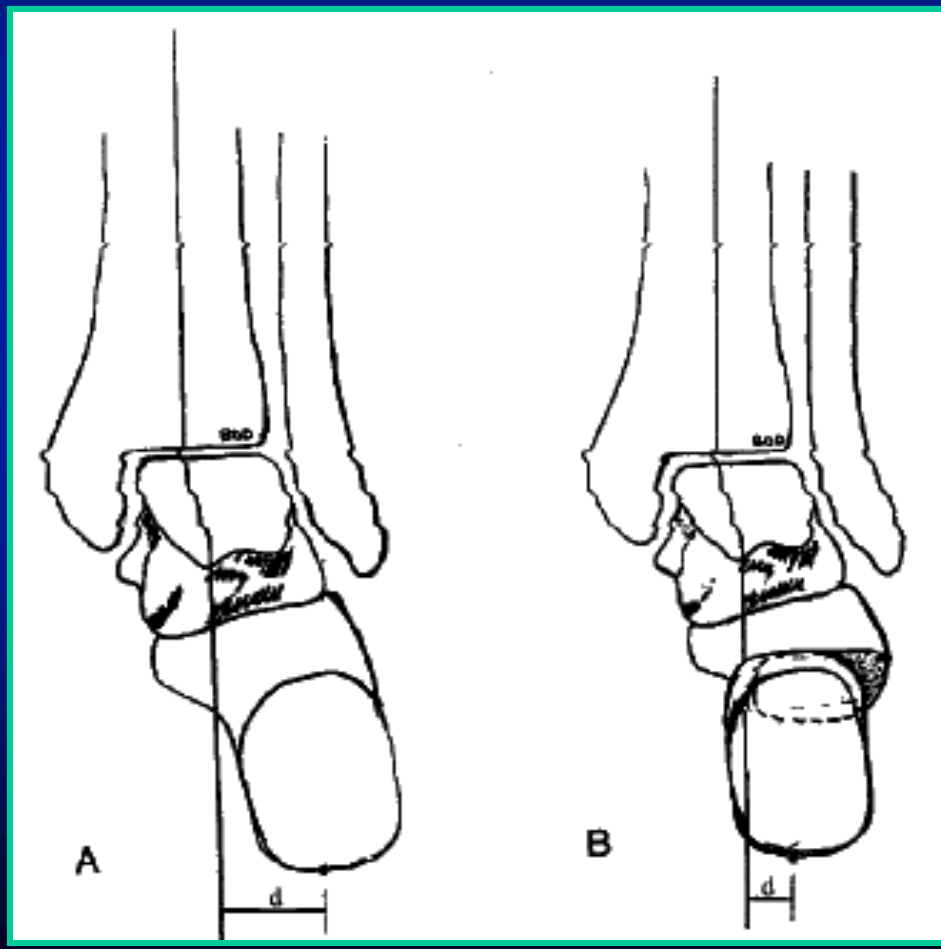

# MDCO RATIONALE

- *Medialize insertion of Achilles tendon*
  - *Decreases deforming pronatory forces*
  - *Creates supinatory STJ moment*
- *Decreases PB antagonistic forces on a relatively weak FDL transfer*
- *Decreases distance between the heel-floor contact point and the long axis of the leg*

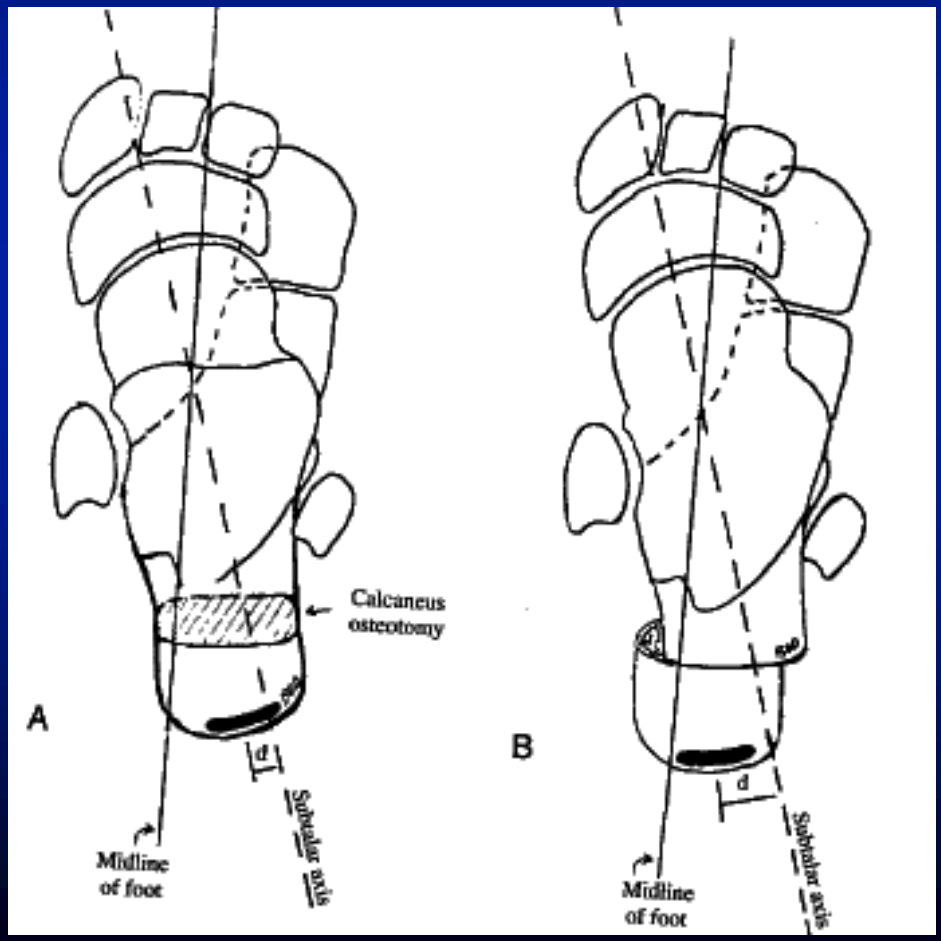

# *The Contribution of MDCO to the Correction of Flatfoot Deformities*

- *Cadaver study to define contribution of Achilles tendon contracture to flatfoot deformity and effect of MDCO*
- *Loading of the achilles tendon increases flatfoot deformity*
- *MDCO significantly decreases the arch-flattening effect of the achilles tendon and eliminates the potential increase in the deformity.*

*Nyska, Parks, Chu, Myerson; FAI, 22:278, 2001*

# *MDCO RATIONALE*

- *Restores proper gastro-soleus function as a heel invertor*
- *Medializes the posterior tuber, increasing supinatory GRF*
- *Maintains STJ ROM*

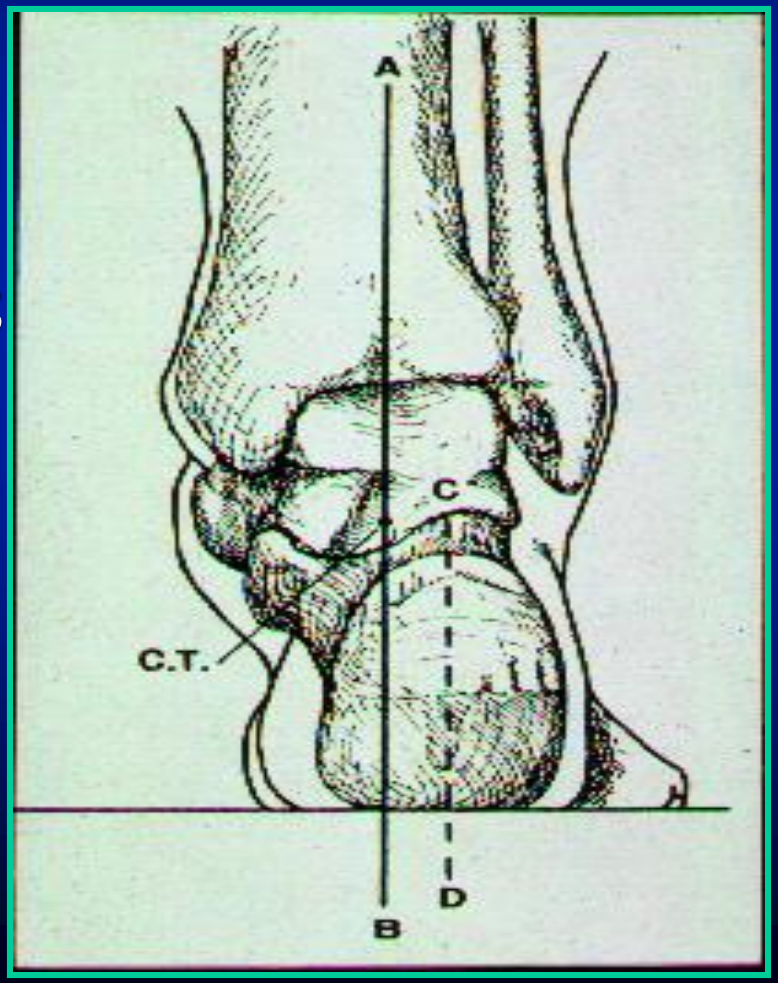

# INDICATIONS

- *Reducible hindfoot valgus*
- *Stable Midtarsal joint*
- *Functional Tritarsal Joints*
- *Minimal forefoot varus*

# Medial Displacement Calcaneal Osteotomy

- *TENDON TRANSFER COMBINED WITH CALCANEAL OSTEOTOMY FOR TREATMENT OF POSTERIOR TIBIAL TENDON INSUFFICIENCY*
  - *18 patients (12-26 m = average follow-up)*
  - *Mean improvement of TFMA = 12.5 degrees*
  - *Mean improvement of TNJ coverage angle = 13 degrees*
  - *Mean improvement of distance of MC to floor = 7 mm*
  - *Will offset the inherent weakness of FDL transfer by reducing the antagonist deforming force of heel valgus*

Myerson et al, FAI; Vol. 16, No. 11, 1995

# Medial Displacement Calcaneal Osteotomy

- *TREATMENT OF STAGE II POSTERIOR TIBIAL TENDON DEFICIENCY WITH FLEXOR DIGITORUM LONGUS TENDON TRANSFER AND CALCANEAL OSTEOTOMY*
  - *129 patients (5.2 yr = average follow-up)*
  - *Mean improvement of AP TFMA = 21 degrees*
  - *Mean improvement of AP TN coverage angle = 21 degrees*
  - *Mean improvement of lat TFMA = 12 degrees*
  - *Mean improvement of distance of MC to floor = 12 mm*
  - ***Subjectively high patient satisfaction***

Myerson et al, FAI 25(7), 2004

# INCISIONAL APPROACH

- *Parallels peroneals*
- *Superior border of calcaneus to inferior border*
- *Avoid sural nerve*
- *Direct to periosteum*

# INCISIONAL APPROACH

- *Parallels peroneals*
- *Superior border of calcaneus to inferior border*
- *Avoid sural nerve*
- *Direct to periosteum*

# EXPOSURE

- *Subperiosteal*
- *Elevate superiorly and inferiorly*
- *Gentle retraction*

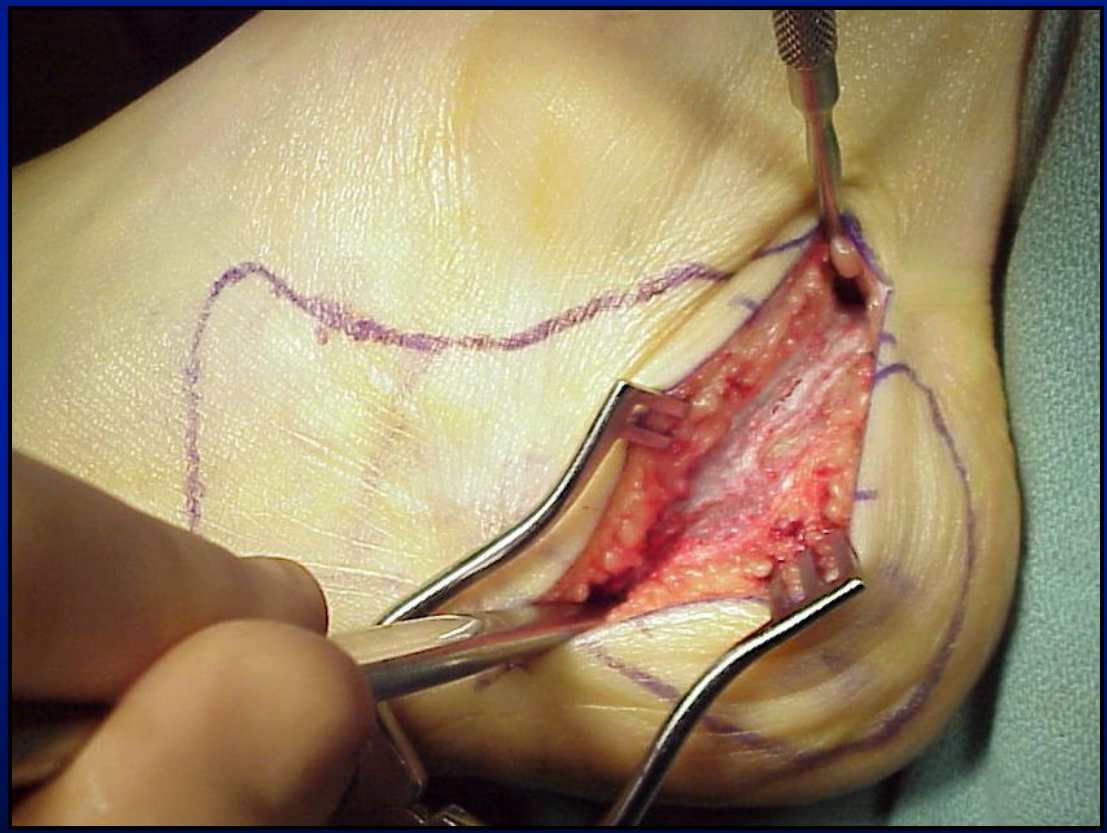

# OSTEOTOMY

- *Anterior to Achilles and plantar tubercle*
- *Transcortical*
- *Proceed with CAUTION medially*
- *Configuration*
  - *Oblique*
  - *L*
  - *Z*

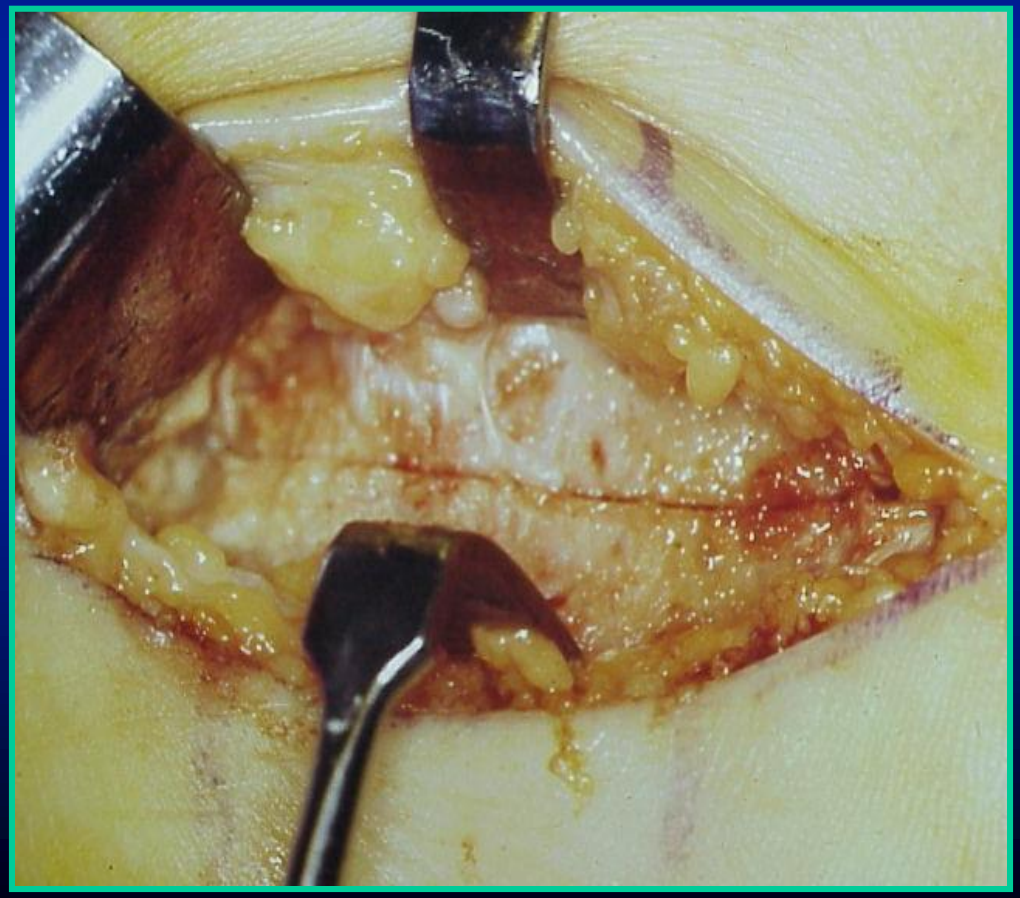

# *Anatomic Study of Medial NV Structures in Relation to MDCO*

- *22 fresh-frozen cadavers*
- *Average of 4 NVS crossed each osteotomy site*
- *Branches of the LPN and MPA may be at risk when performing MDCO (lateral approach)*
- *Risk of pain, numbness and hematoma*
- *Osteotomy thru medial cortex must be performed in a carefully controlled manner*

*Greene et al, FAI: 22:569-571, 2001*

# MEDIAL DISPLACEMENT

- *Lamina spreader*
  - *"Periosteal Stretching"*
- *Plantarflex the ankle*
- *Medial displacement*
  - *10mm*

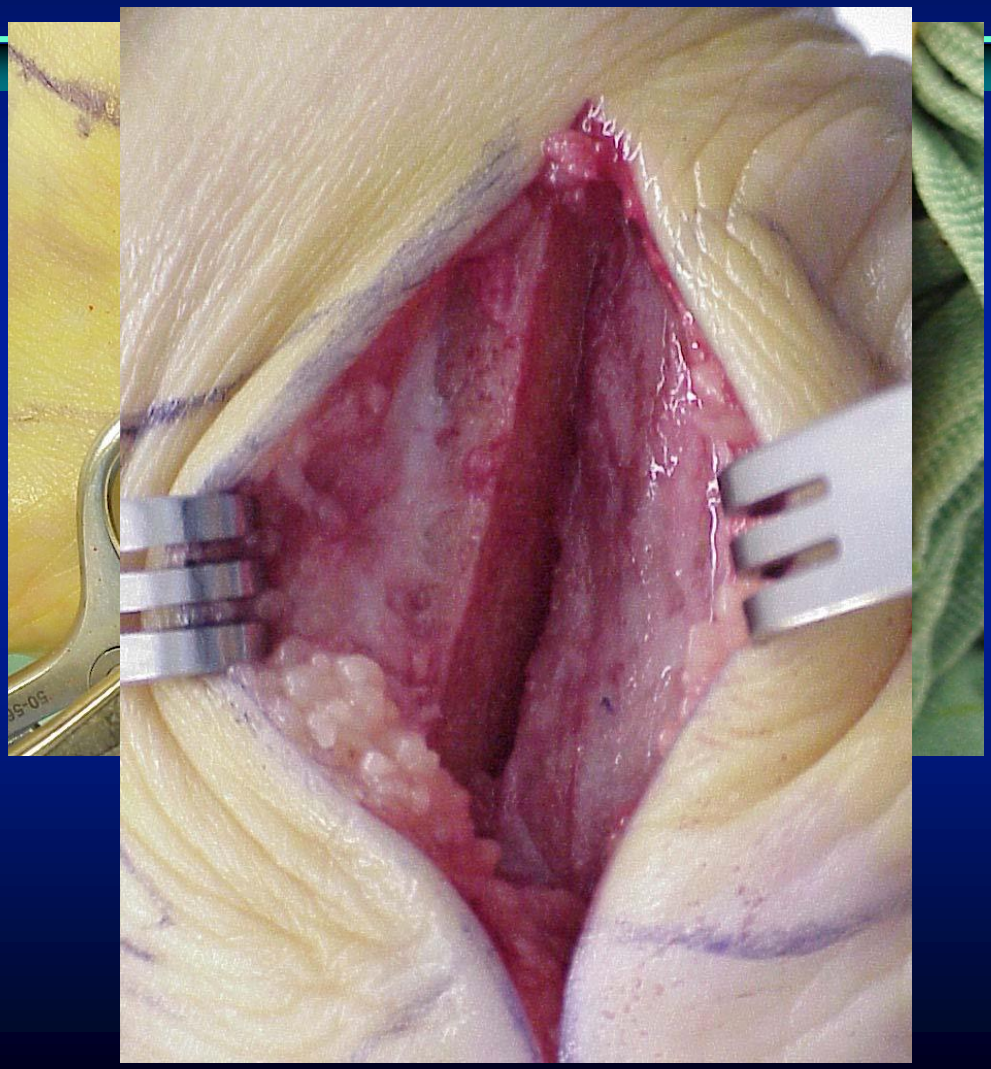

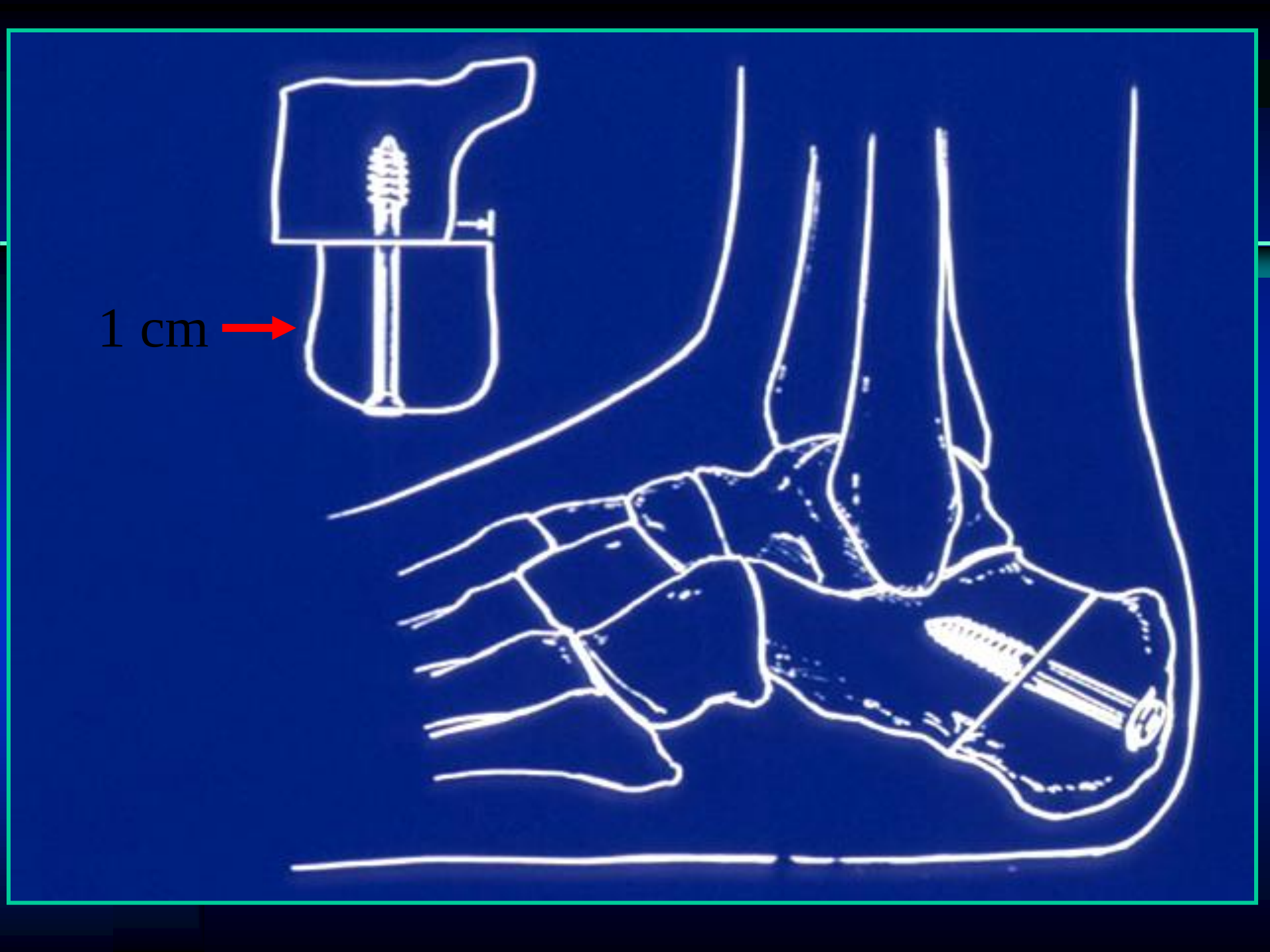
1 cm

# FIXATION

- *Large caliber cannulated screws*
  - *6.5, 7.3, 8.0*
  - *Headless???*
- *Posterior to anterior*
- *Fluoroscopy*
  - *Lateral*
  - *Axial view*

# *MDCO Complication*

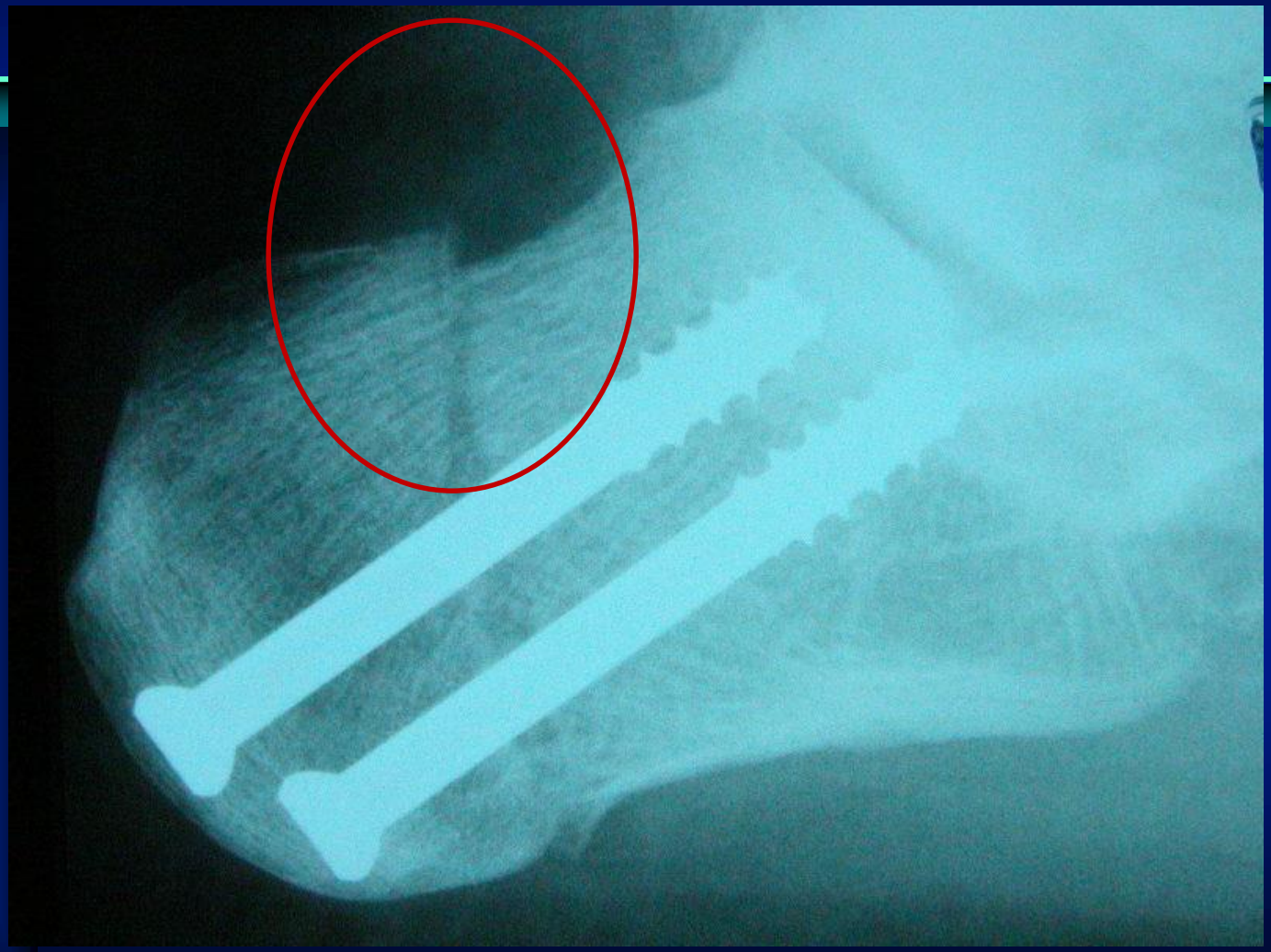

# *MDCO "Z" Technique*

# *MDCO "Z" Technique*

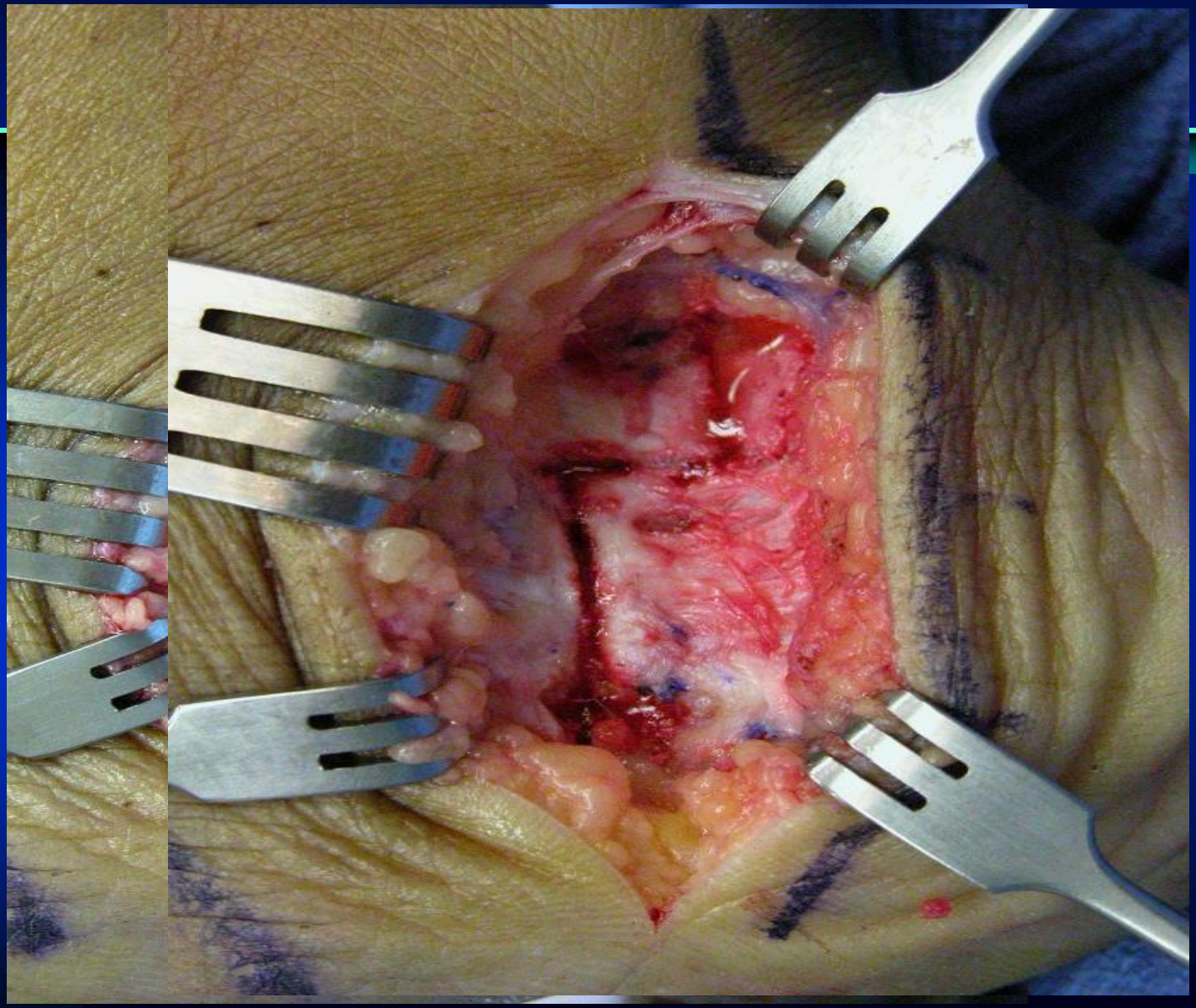

# *MDCO "Z" Technique*

# Effects of MDCO on Tibiotalar Joint & Spring Ligament

- *1 cm medializing osteotomy moves the center of pressure of the ankle joint 1.58 mm medially*
  - *Steffensmeier et al,J Orthop Res, Vol 14,1996*
- *In vitro studies have shown that a 1 cm medializing MDCO decreases strain on the spring Ligament*
  - *Otis et al: Foot Ankle Inter, vol.20 (4):222, 1999*
  - *Arangio and Salathe. Clinical Biomechanics 16(2001).*
- *…And Deltoid Ligament*
  - *Resnick et al, FAI, 16:14-20,1995*

# *Double Calcaneal Osteotomy*

- *Evans combined with MDCO*
- *Late stage 2 PTTD*
- *Reported success for PTTD in adults*
- *Less severe displacements at both sites*

# *Double Osteotomy + Tendon Transfer for Stage II PTTD*

- *28 cases with mean follow-up of 5 years*
- *MDCO, Evans, FDL transfer and TAL*
- *14%(4 pts) displayed radiographic signs of CC joint arthritis at 5 year follow-up*
- *One required arthrodesis*
- *Radiographic measurements demonstrate maintenance of correction of the adult acquired flatfoot*
- *Rebalances mechanical forces with "less severe displacements" at both sites*
- *High patient satisfaction*

*Moseir-LaClair, Pomeroy, Manoli; FAI, #22:283-291, 2001*

# Double Calcaneal Osteotomy

# Double Calcaneal Osteotomy

- *Effective in late stage II PTTD*
- *Preserves hindfoot motion*
- *CCJ arthrodesis has higher morbidity, increased number of complications and extended convalescence relative to the Evans osteotomy.*

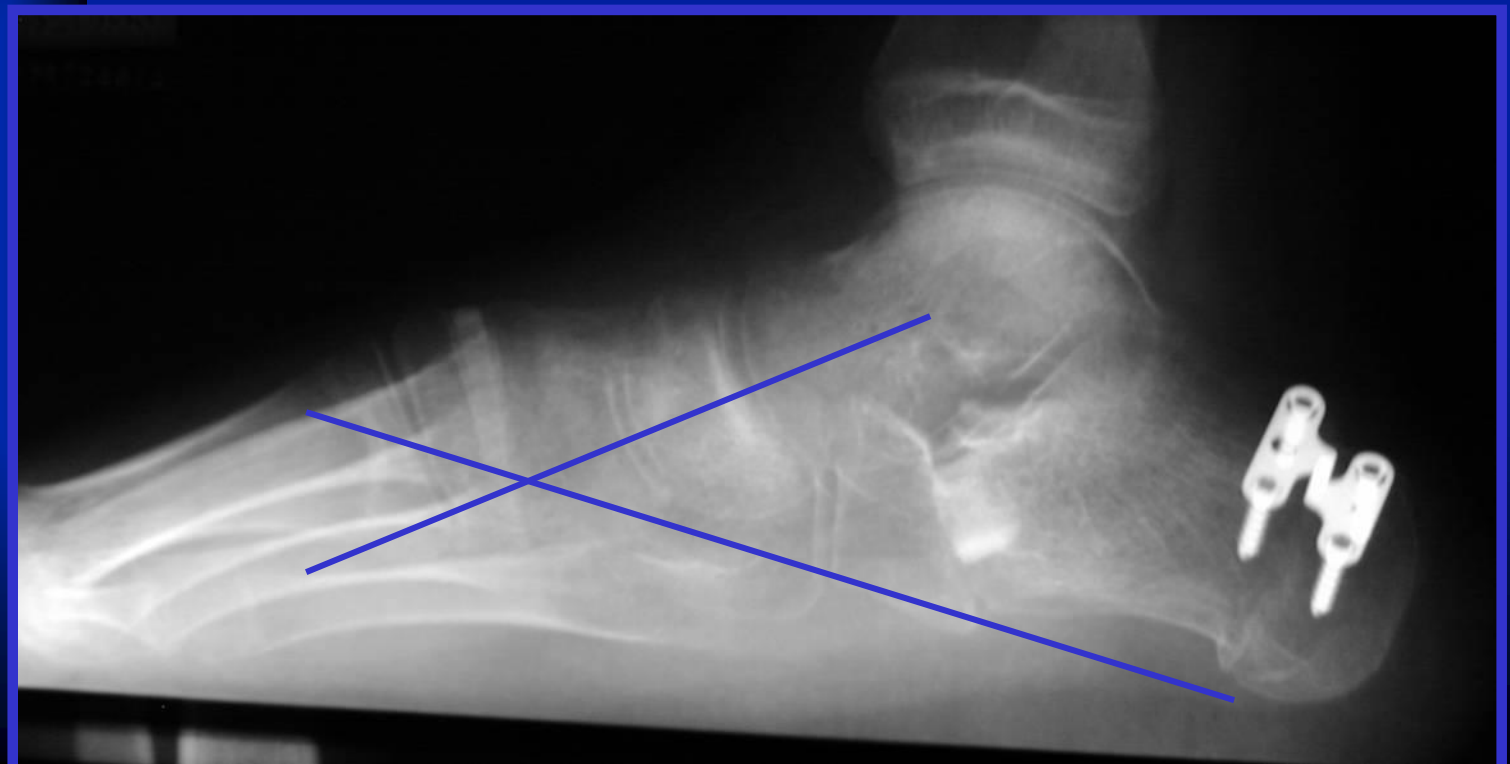

# *SUMMARY*

- *STAGE II PTTD*
- *TRIPLANAL CORRECTION*
- *RESTORE TRIPOD*
- *MAINTAIN HINDFOOT MOTION*
- *CALCANEAL OSTEOTOMIES:*
  - *MTJ LOCKED: MDCO*
  - *MTJ UNLOCKED: EVANS*
  - *SEVERE: DOUBLE*
- *BALANCE MUSCLE IMBALANCE*