Addressing Plantar Plate Pathology

July 27, 2017
APMA Annual Scientific Meeting
Nashville, TN

Chad E. Webster, DPM, FACFAS, FASPS

President, Tennessee Podiatric Medical Association

Memphis, TN

Mid-South Foot & Ankle Specialists
msfas.com

TPMA
Tennessee Podiatric Medical Association



Plantar Plate Pathology

Goals:

- ✓ **Anatomy**
- ✓ **Pathophysiology**
- ✓ **Physical Examination**
- ✓ **Diagnostic Findings**
- ✓ **Treatment Options**

ANATOMY OF THE MTPJ

- **THE MTPJ'S REST ON A SUSPENSION BRIDGE LINKED TO THE PLANTAR FASCIA**

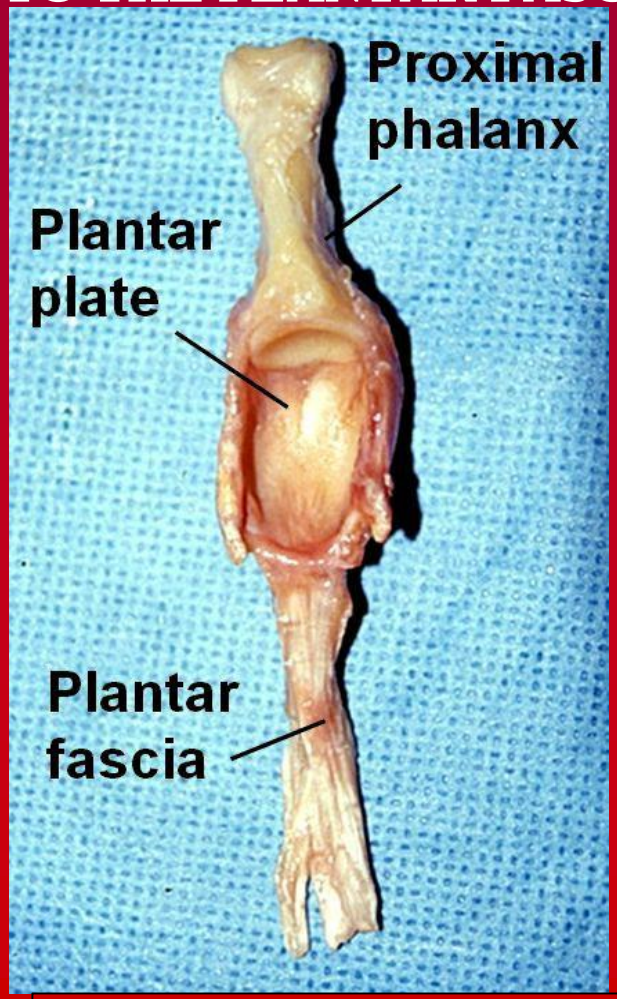

Lawrence Ford, DPM, *Podiatry Today,* April 2017

Pathophysiology of Lessor MTPJ

- ✓Repetitive Increased load/stress @ MTPJ
- ✓Acute Injury can destabilize MTPJ
- ✓Plantar fascia function related to plantar plate
- ✓Extension as position of function in foot

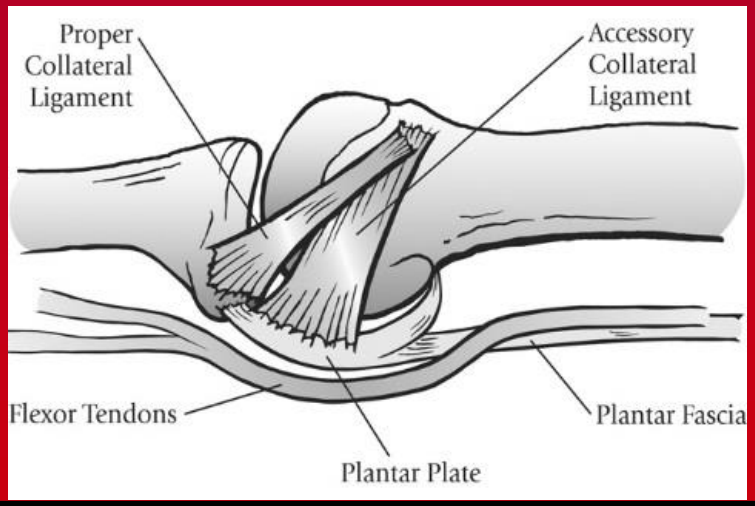

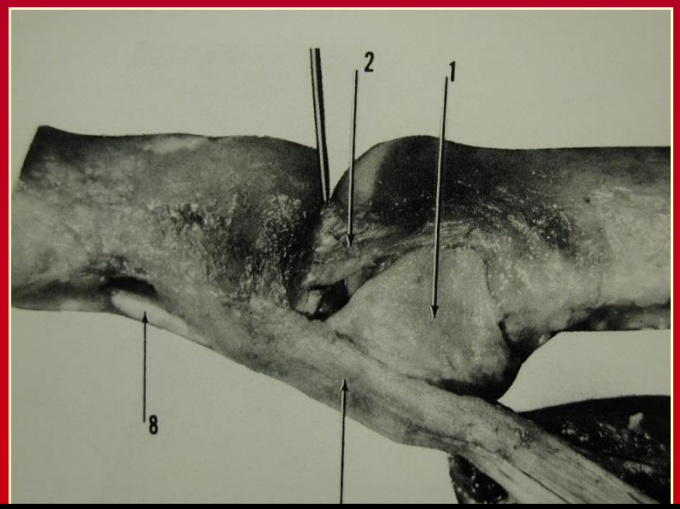

Kirby K., Understanding The Biomechanics of Plantar Plate Injuries. *Podiatry Today:* 30-38, April 2017

Doty JF, Coughlin MJ, Wiel L Jr, Nery C. Etiology & management of lessor toe metatarsophalangeal joint instability. *Foot Ankle Clin.* 2014;19(3):385-405.

Listen to Patient History & Chief Complaint

- Plantar Pain
- Plantar swelling
- Deformity/Deviation of the 2nd Toe
- "Toe is raising up more"
- Feels like marble under ball of foot.

Physical Examination

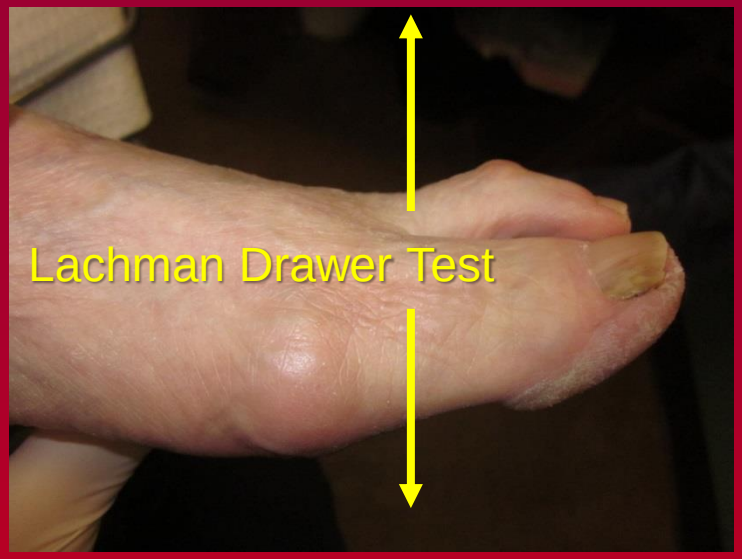

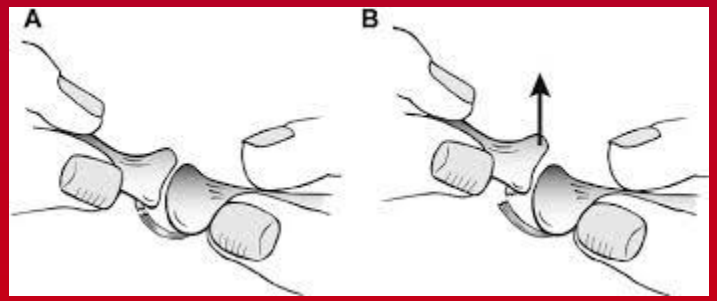

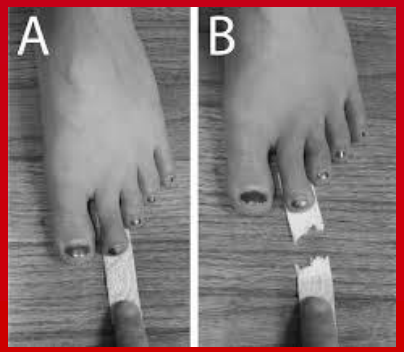

Paper Pull-Out Test

- **OPEN CHAIN –Active flexion of the toes reveals isolated extension of the 2nd toe (prox. phal.)**

Diagnostic Findings

X-RAYS

Clinical examination of plantar plate abnormality: a diagnostic perspective.
Klein EE, Weil L Jr, Weil LS Sr, Coughlin MJ, Knight J. Foot Ankle Int. 2013 Jun;34(6):800-4. doi: 10.1177/1071100712471825. Epub 2013 Jan 14.

SAGITTAL MRI

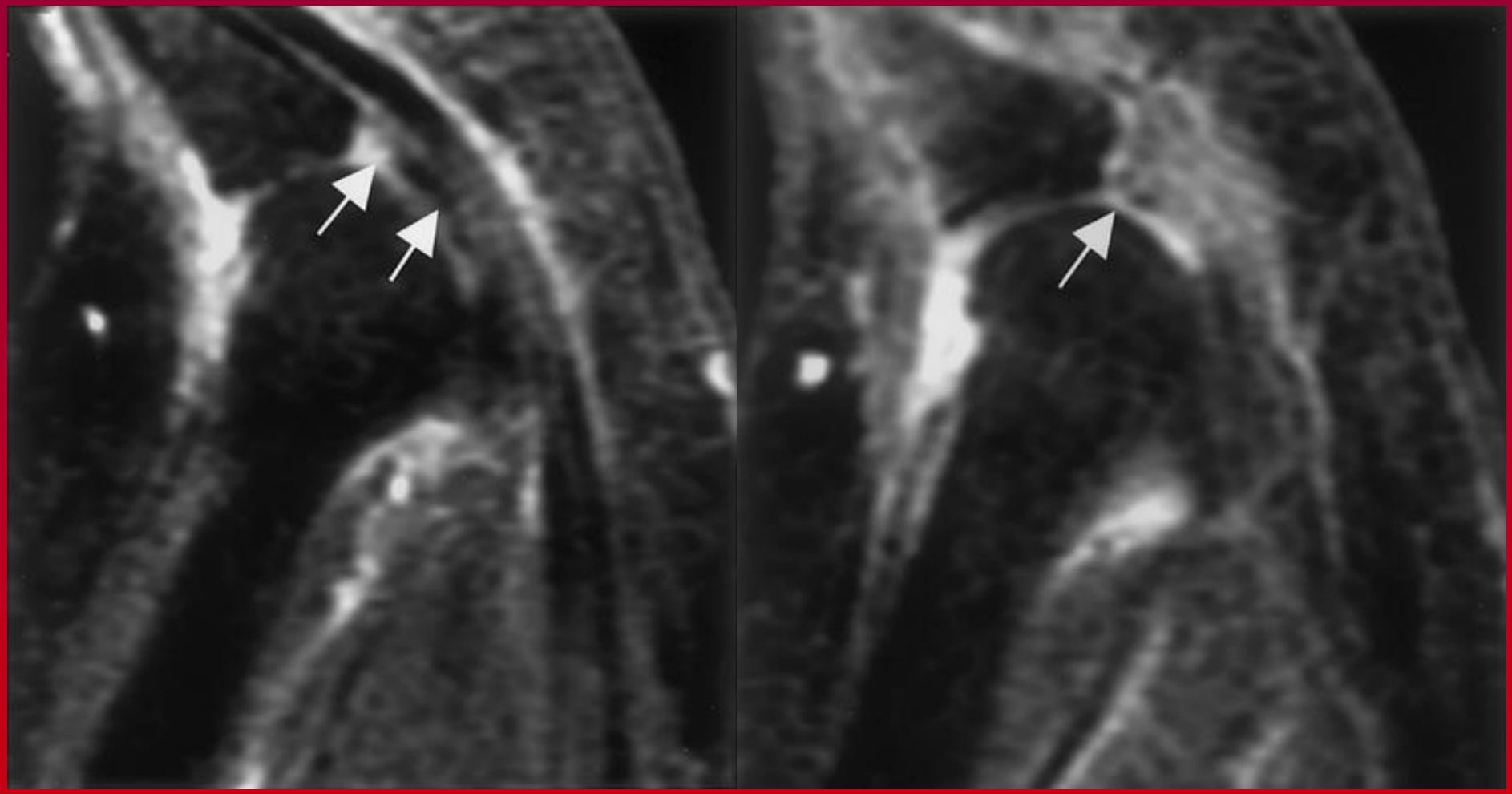

Magnetic resonance imaging versus musculoskeletal ultrasound for identification and localization of plantar plate tears.
Klein EE, Weil L Jr, Weil LS Sr, Knight J. Foot Ankle Spec. 2012 Dec;5(6):359-65. doi: 10.1177/1938640012463061. Epub 2012 Oct 16.

Diagnosis of plantar plate injury by magnetic resonance imaging with reference to intraoperative findings.
Sung W, Weil L Jr, Weil LS Sr, Rolfes RJ.J Foot Ankle Surg. 2012 Sep-Oct;51(5):570-4. doi: 10.1053/j.jfas.2012.05.009. Epub 2012 Jun 21

Ultrasound Images

Role of magnetic resonance imaging versus ultrasound for detection of plantar plate tear
Xin D, Lang L, Dai-Qing W, Ming L, Zhu X. J Orthop Surg Res. 2017; 12: 14.

Musculoskeletal ultrasound for preoperative imaging of the plantar plate: a prospective analysis.
Klein EE, Weil L Jr, Weil LS Sr, Knight J.Foot Ankle Spec. 2013 Jun;6(3):196-200. doi: 10.1177/1938640013484795. Epub 2013 Apr 4.

Plantar Plate Pathology Staging System

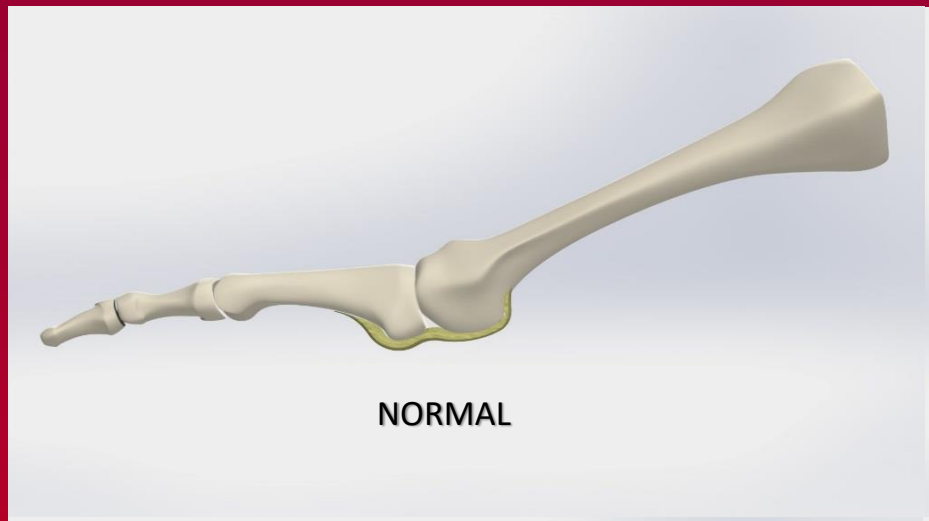

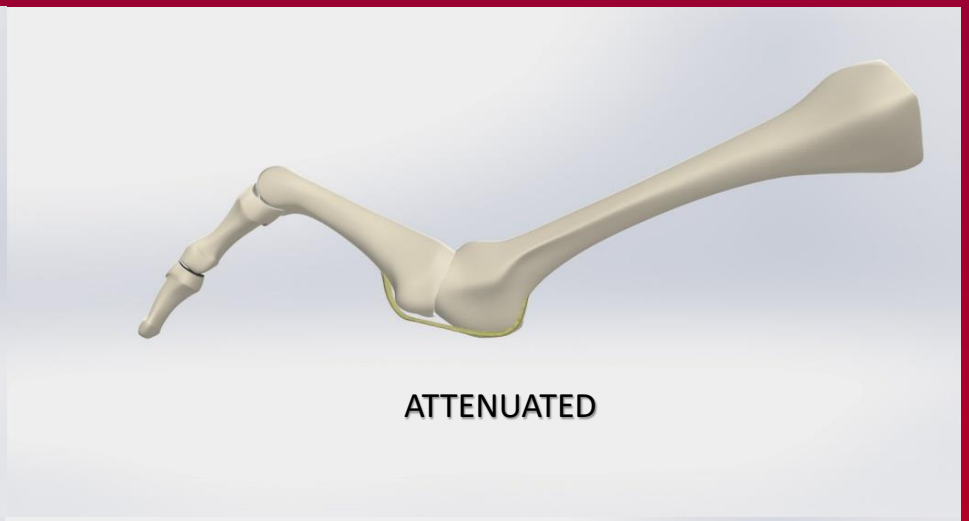

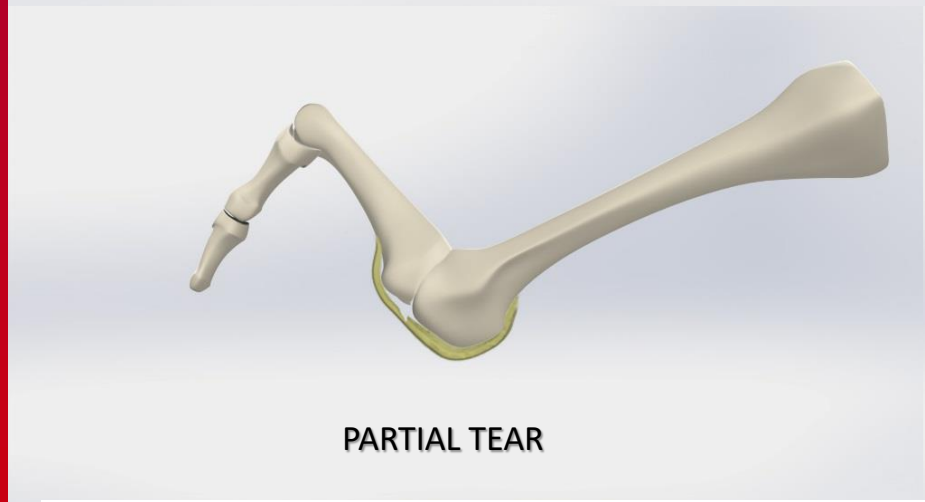

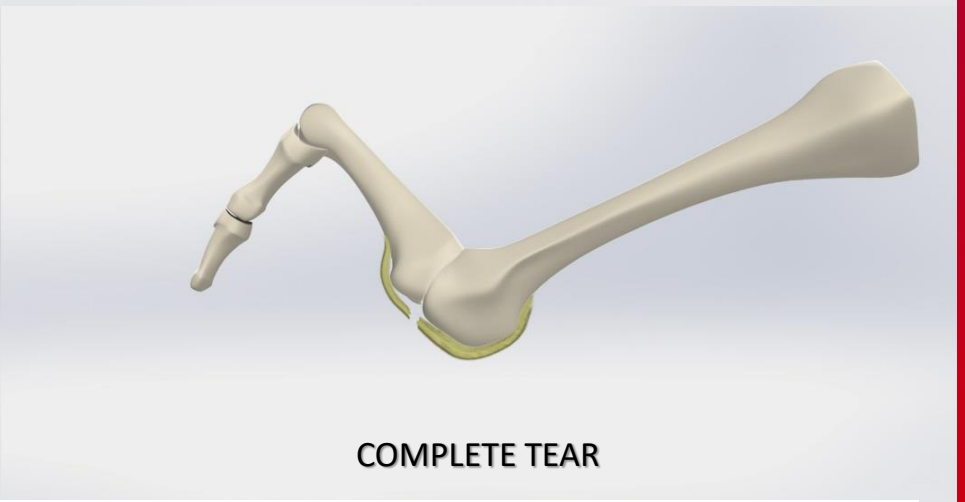

Coughlin MJ. Proposed a comprehensive clinical staging system based on physical exam. In: Surgery of the foot and ankle. 9th edition. Philadelphia: Mosby Elsevier Inc; 2007. p. 366-400

Nery C etc al. Found high correlation between staging and surgical findings in 55 plantar plate tears. Lessor MTPJ Instability: Prospective evaluation repair of plantar plate. *Foot Ankle Int. 2012; 33:301-11*

Treatment Options:
Conservative → Surgical

Nonoperative Treatment of a Lessor Toe Plantar Plate Tear with Serial MRI Follow-up: A Case Report
Jordan M, Thomas M, Fisher W. *J Foot & Ankle Surgery.56(2017) 857-861.*

Surgical Treatment Options: Considerations & Controversy

- Doral vs. Plantar Approach for Repair
- Metatarsal Osteotomy vs. No Osteotomy
- Plantar Plate Repair vs. FDL Transfer

Plantar Approach

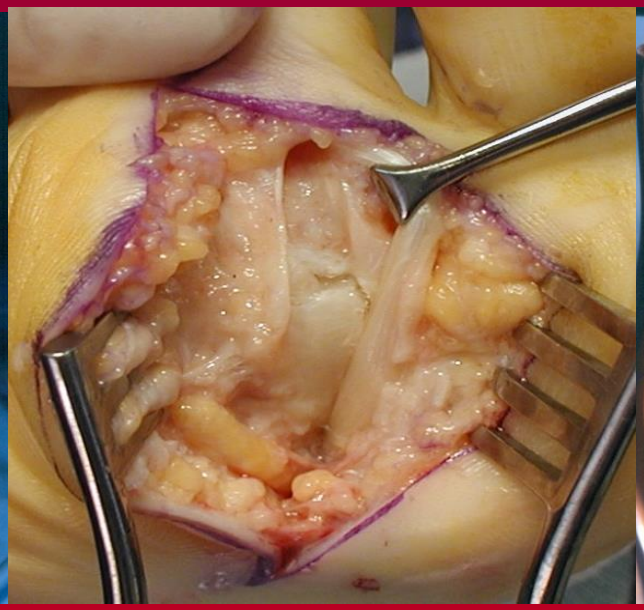
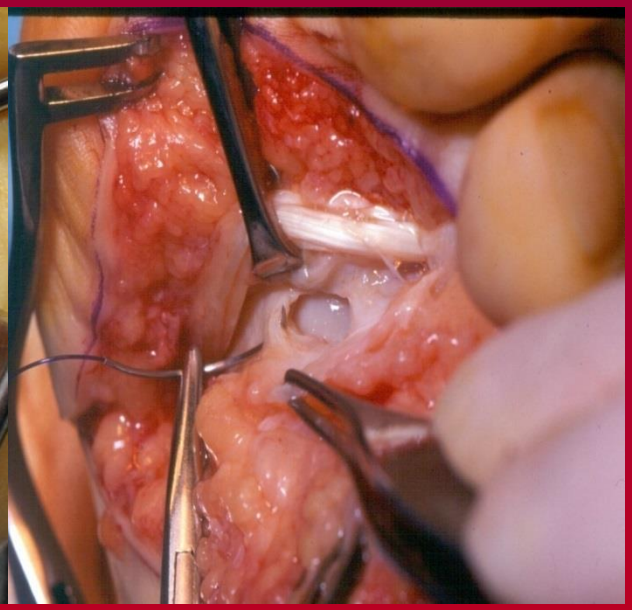

Plantar Plate Repair Using a Direct Plantar Approach: An Outcome Analysis
Prissel M, Hyer C, Donovan J, Quisno A. *J Foot & Ankle Surg* 56(2017) 434-439

- Results demonstrated that is approach provides excellent postoperative pain relief, improvement of the associated disability, and improvement in activity limitations.

Dorsal Approach

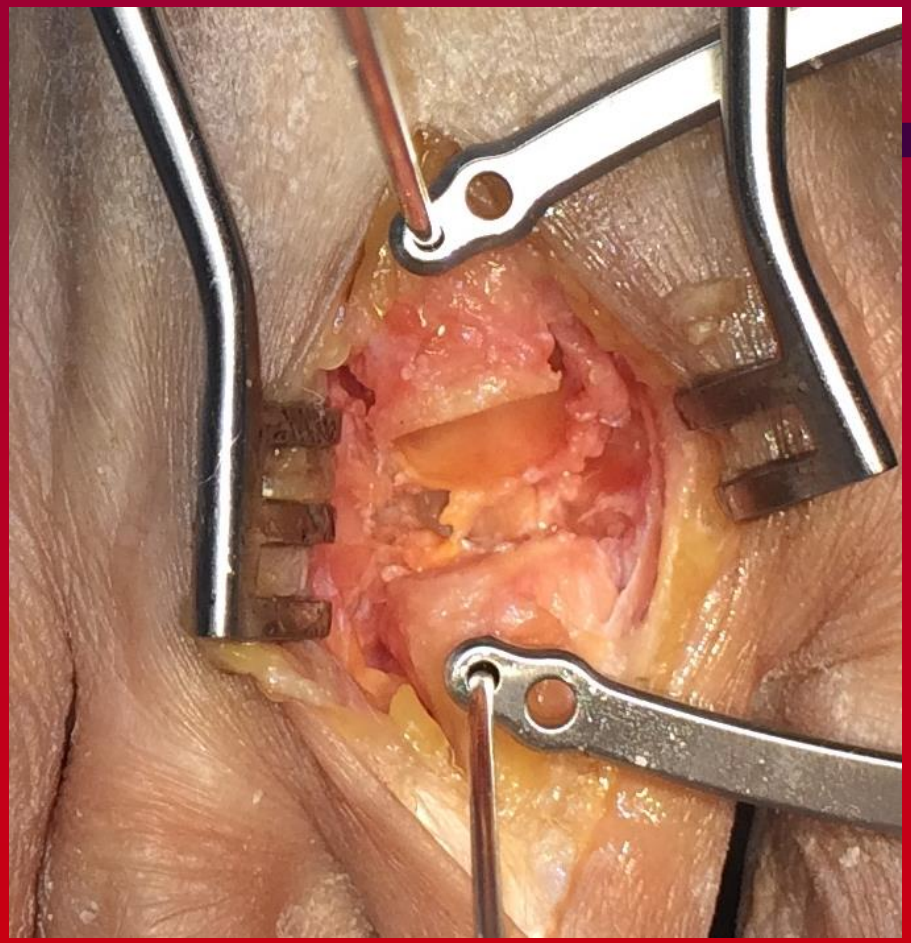

No Plantar Incision = WB Earlier

No Plantar Scar

Metatarsal Osteotomy vs. No Osteotomy

Fleischer et al. Association of Abnormal Metatarsal Parabola with Second Metatarsophalangeal Joint Plantar Plate Pathology. Foot & Ankle Int. Vol. 38(3) 289-297.

- Found that long 2nd metatarsal was a risk factor for developing 2nd MTPJ Plantar Plate Tears.

Waverly et al. Does Second Metatarsal Length Correlate with Plantar Pressure Measurements Beneath the Second Metatarsophalangeal Joint During Walking? Oral presentation at 2017 ACFAS Annual Scientific Conference Manuscript Competition, Las Vegas, NV, February 27, 2017. (First Place)

- Study shows that a relatively elongated 2nd metatarsal is associated with increased sub-second metatarsal head plantar pressure during ambulation.
- Elongated 2nd metatarsal is potential contributor to metatarsalgia that can lead to plantar plate injuries.

Plantar Plate Repair vs. FDL Transfer

Myerson M, Hung H. The Role of Toe Flexor-to-Extensor Transfer in Correcting Metatarsophalangeal Joint Instability of the Second Toe. *Foot & Ankle Intl. 26:675-679, 2005*

- 64 feet: 29 feet very satisfied, 15 satisfied minor reservations, 6 major reservations, 14 patients unhappy
- Function of 2nd toe improved, most had pain relief, substantial number patients dissatisfied because stiffness toe

Haddad SL, et al. Results of flexor-to-extensor & extensor brevis tendon transfer for correction of crossover 2nd toe deformity. *Foot & Ankle Intl. 20:781-788, 1999*

- Flexor-to-extensor tendon transfer is appropriate for rigid stage 3 & stage 4 deformities and all patients with symptomatic neuroma of 2nd web space.
- Stiffness of the MTP joint is a potential problem with flexor-to extensor tendon transfer.

Plantar Plate Repair vs. FDL Transfer

Flint WW, Macias, DM, et al. Plantar Plate Repair of Lessor Metatarsophalangeal Joint Instability. *Foot & Ankle Intl. 38(3)234-242, 2016*

- 97 feet with 138 plantar plate tears, dorsal approach with Weil osteotomy followed for 12 months.
- Eighty of patients scored “good” to “excellent” satisfaction scores at 12 months.
- VAS Pain Score 5.4/10 pre-op & 1.5/10 post-op

Plantar Plate is thin or almost gone

FDL AUGMENTATION

- **SUTURES ARE PASSED THROUGH THE FDL WHILE IT IS HELD UNDER TENSION = REINFORCE PLATE**

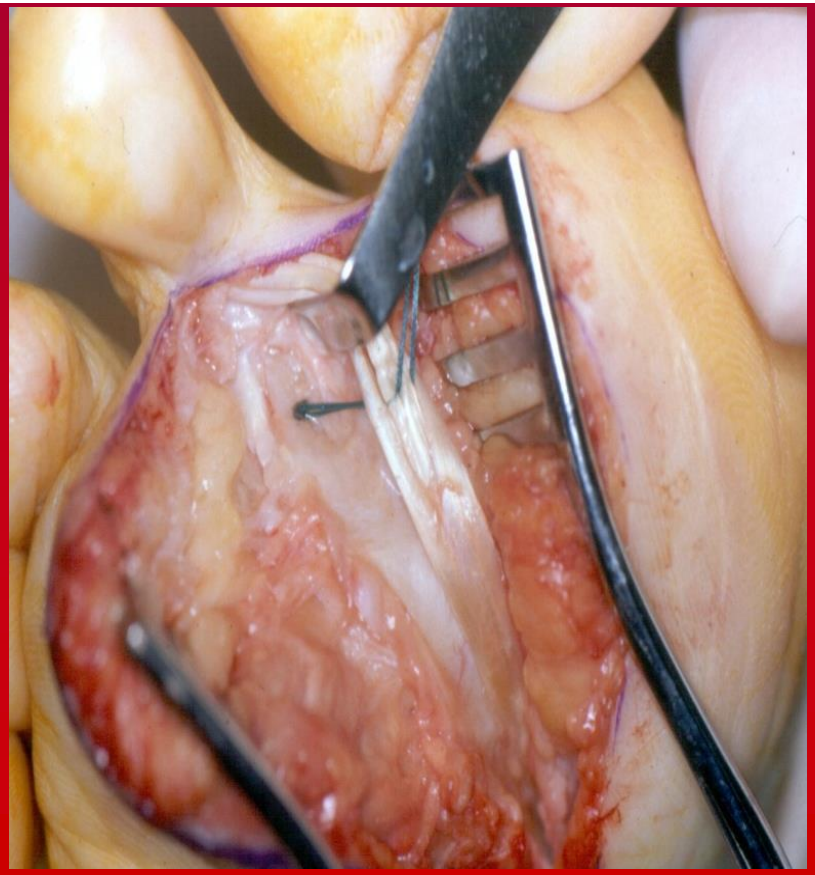

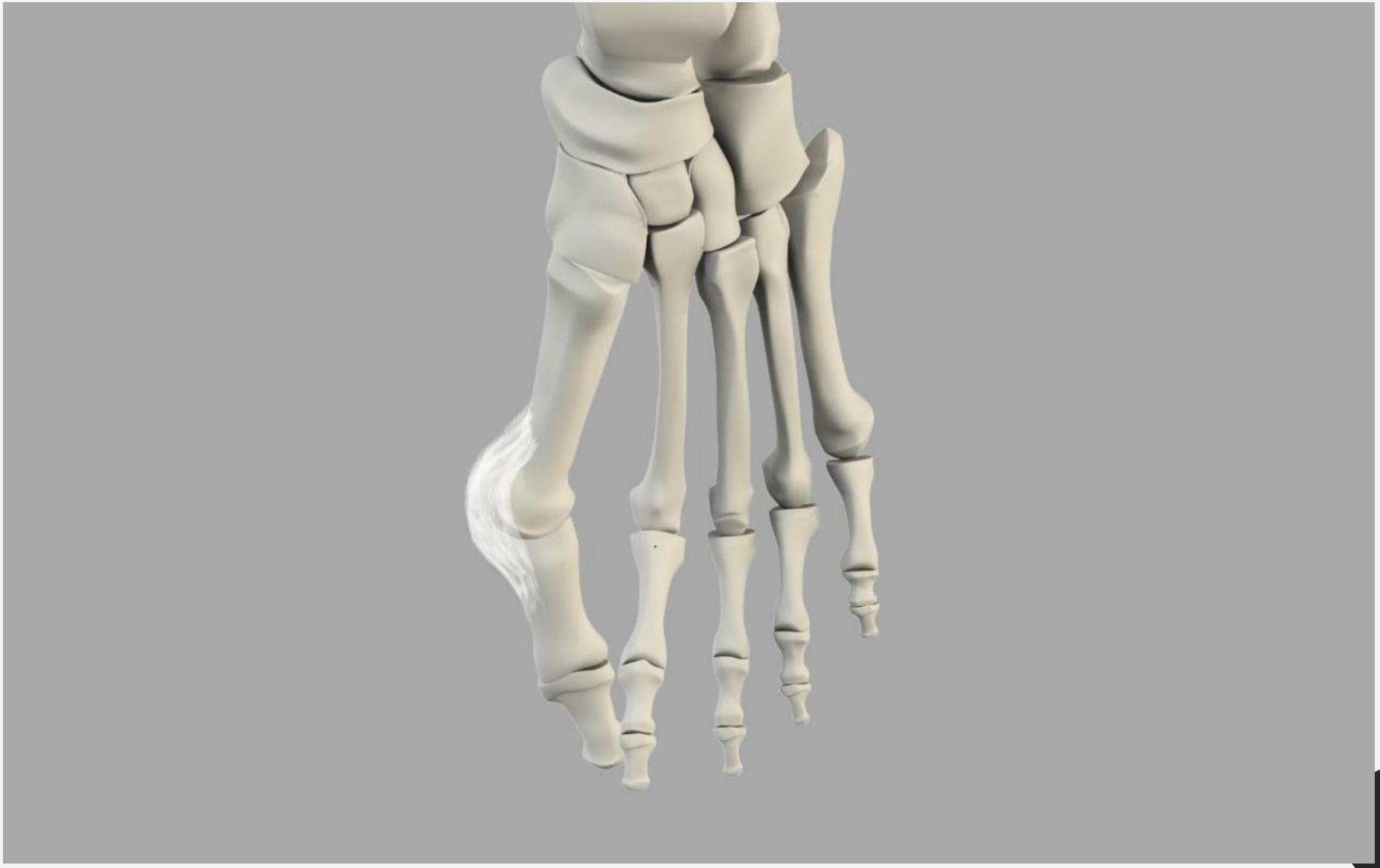

Plantar Plate Pathology

Weil Osteotomy Thoughts

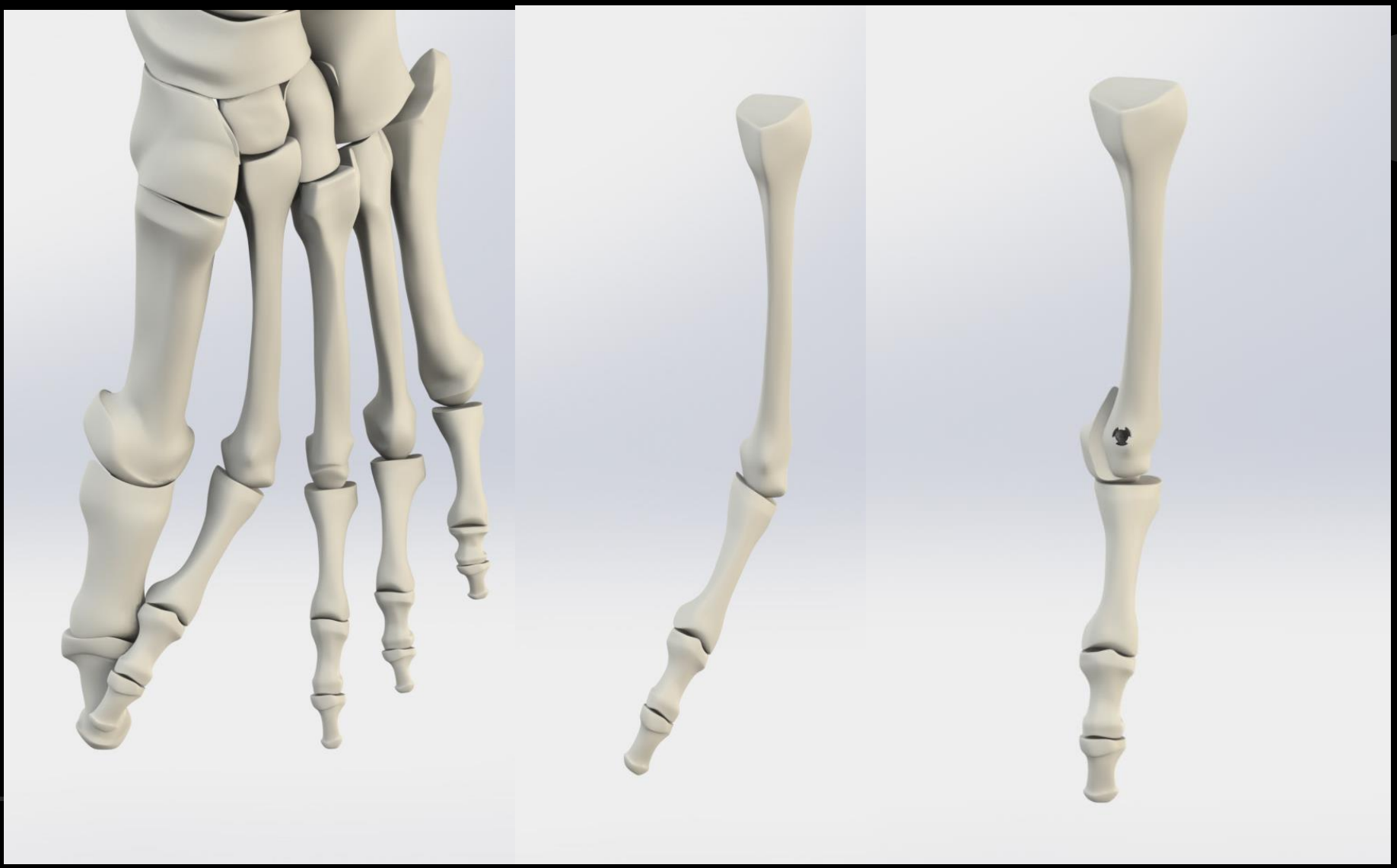

Addressing Plantar Plate Pathology

CONCLUSIONS

- Deformity and Instability of the 2nd MTPJ is likely plantar plate disruption (attenuation, rupture, or dislocation)
- Dorsal and Plantar approaches have demonstrated good post operative results in recent studies and new instruments/techniques.
- New studies demonstrate length of 2nd metatarsal needs to be evaluated preoperatively and addressed if long.
- Flexor-to-extensor tendon transfers should be considered in stage 3 and stage 4 deformities.
- To address this subluxation of MTPJ, long metatarsal, plantar plate tear deformity: bone and soft tissue needs to be considered.


29
USA
ROCK & ROLL SINGER, 1935–1977
KING, THE
ELVIS

Thank You!


29
USA
ROCK & ROLL SINGER, 1935–1977
KING, THE
ELVIS

Plantar Scar

Dorsal Scar